

Plasma Skin Resurfacing: Personal Experience and Long-Term Results

Stuart H. Bentkover, MD

KEYWORDS

- Nitrogen plasma • Skin resurfacing • Neocollagenesis
- Hyper pigmentation • Skin regeneration
- Wrinkle severity rating scale

PERSPECTIVES ON SKIN RESURFACING

The most common objectives of a facial resurfacing technique are to remove wrinkles or scars and rejuvenate skin. Rejuvenation may include improvements in texture and uniformity in color. The various machines and techniques accomplish their results with varying depths of epidermal and dermal penetration, and stimulation of neocollagenesis. Before the introduction of aesthetic uses for the carbon dioxide laser in the mid-1990s, mechanical dermabrasion with a diamond fraise or wire brush and various chemical peels were the predominant treatments. Mechanical dermabrasion is less prevalent today. Medium-depth and deep chemical peels are still performed successfully by many medical practitioners, and superficial peels are now commonly done in medical and nonmedical spalike settings.

Principles of Lasers

Lasers function according to the principles of photothermolysis. Each laser commonly delivers a light of a pure, single color (wavelength) to the skin. The part of the skin targeted by the laser is related to the color of the laser light and the color of the target (chromophore) in the skin. Each laser wavelength has a complementary color or range of colors that best absorb the wavelength of the light it produces. For the carbon dioxide laser (10,600 nm),¹ for example, the primary target of the laser is water. Because skin cells are mostly

water, the laser targets these cells and vaporizes them in a very controlled and precise manner. Some lasers combine more than 1 wavelength to selectively target more than 1 chromophore.

Lasers for Skin Rejuvenation

Common lasers for skin rejuvenation are the 10,600-nm carbon dioxide laser, the 2940-nm erbium:YAG laser,² and the fractionated erbium 1550-nm and 1410-nm lasers.³ The introduction of fractionated technology brought some practical solutions for patients requesting procedures that could be done with shorter postprocedure downtime under local anesthesia. Fractionated technology provides a means of delivering the laser beam in distinct columns of light spaced so as to spare tissue between adjacent targeted areas. This tissue sparing leads to shorter healing times and less tissue ablation. Full ablative laser treatments are also still popular for maximum wrinkle reduction and skin rejuvenation, if a patient will accept a few more days of downtime.

Neocollagenesis

The appropriate technology for a particular patient depends on the depth of the wrinkles or scars to be treated, how much excess pigment, solar elastosis, or other signs of sun damage prevails, how the patient's skin will react to light and heat, and the amount of downtime the patient will tolerate. While all of the various techniques will

Disclosures: Medical Education Faculty of Merz Aesthetics; Medical consultant to former Rhytec, Inc, which no longer exists.

Private Practice, Bentkover Facial Plastic Surgery & Laser Center, 123 Summer Street, Suite 675, Worcester, MA 01608, USA

E-mail address: stuart.bentkover@drbentkover.com

Facial Plast Surg Clin N Am 20 (2012) 145–162

doi:10.1016/j.fsc.2012.02.010

1064-7406/12/\$ – see front matter © 2012 Elsevier Inc. All rights reserved.

mechanically or chemically peel the epidermis, the amount of heat delivered to the skin and the depth of that heat penetration are major determinants of the amount of neocollagenesis that actually tightens the dermis. The depth of penetration for each laser depends on the wavelength of the target chromophore, the number of passes, and the amount of laser energy delivered. Typical depths of penetration are as follows:

| | | |
|----------------------------|-----------|--|
| Carbon dioxide | 10,600 nm | 450 μm to 1–2 mm (though rarely beyond 1 mm) ¹ |
| Erbium:YAG | 2940 nm | 3–120 μm^2 |
| Erbium fiber, diode pumped | 1550 nm | 250–800 μm^3 |

The Introduction of Plasma Technology

Portrait PSR³ is a Class II nonlaser device that provides many of the same advantages of a laser as well as reasonably short postprocedure downtime. Introduced into the United States market for cosmetic use by Rhytec, Inc (Waltham, MA, USA) in 2005, it is a machine that produces nitrogen plasma in its hand piece. (Energist Group [Swansea, UK] now owns the manufacturing rights and distribution rights for the device, spare parts, and service.)

Plasma, an ionized gas, is the fourth state of matter. The explosions off the sun's surface, electrical storms, and the Aurora Borealis all contain plasma. Plasma television sets, though now largely replaced by LCD and LED technology, are commonplace today. Plasma technology is nothing new to medicine.⁴ Unlike surgical cautery devices that produce plasma, the Portrait hand piece does not touch the skin. Nitrogen plasma is delivered to the skin in one or more passes in a technique similar to that of laser resurfacing (Fig. 1). An ultrahigh-frequency pulse of radiofrequency energy driven through a tungsten element ignites nitrogen gas flowing through the hand piece. This pulse of energy converts the stable nitrogen gas to unstable, ionized nitrogen plasma (see Fig. 1).

Portrait is approved by the Food and Drug Administration (FDA) for treating facial and nonfacial rhytids, acne scars, and superficial benign skin lesions such as seborrheic keratoses, viral papillomata, and actinic keratoses in Fitzpatrick skin types 1 through 4. The author has been using this device since July 2006 and has also successfully treated benign skin lentiginos. If there is any question of malignancy, the lesion is biopsied first.



Fig. 1. Portrait PSR³ device and hand piece. (Courtesy of Energist Group, Nyack, NY & Swansea, Wales, UK; with permission.)

The device is contraindicated for nursing or pregnant mothers and in patients prone to keloid formation. In accordance with the original protocols, all retinols are discontinued for 4 to 6 weeks before the treatment.

PLASMA SKIN REGENERATION IS A RESURFACING TECHNIQUE

This technology, though originally labeled plasma skin regeneration (PSR), is truly a skin-resurfacing technique. The heat generated in the dermis is ablative enough to stimulate neocollagenesis. The efficacy of this technology is well established in the literature, and the new collagen produced

is essentially vertically oriented, as is normal collagen.⁵⁻⁷ Typical penetration is to 500 to 600 μm in normally hydrated skin at energies over 3.0 J.⁸ It can be used as a single or multiple treatment modality with well documented neocollagenesis in both modes, significant decreases in facial rhytids, and overall improvement in the general appearance of facial, neck, chest, and dorsal hand skin.⁵⁻¹³ Although not as efficacious in treating acne scars as the carbon dioxide laser, it can improve some acne scarring by as much as 34%.¹¹

Holcomb and colleagues¹⁴ have demonstrated the safety and enhanced results that are possible when combining facelift and cosmetic eyelid surgery with plasma resurfacing, and also gave very specific recommendations for technique and energy levels to be used.

OUR PROTOCOL FOR PLASMA SKIN RESURFACING

Skin Preparation

Before recommending any resurfacing technique, a thorough family and personal history are important. Specifically, it is important to determine the patient's propensity for postinflammatory hyperpigmentation. In New England, we (the author's group) see many patients who appear to have Fitzpatrick type-3 skin with a significant propensity for hyperpigmentation. European lineage mixed with Native American lineage and French Canadian lineage mixed with Native American lineage are commonplace in our population. After taking a careful history of the patient's sun exposure habits and how the patient's skin has reacted to severe sun exposure in the past, we often treat these patients as we would patients with Fitzpatrick type-4 skin (see Operative Technique). All patients are pretreated with 4% hydroquinone for 4 to 6 weeks before the treatment. Hydroquinone is restarted 7 to 10 days after the treatment. Retinols are discontinued 6 weeks before treatment. We routinely pretreat our patients scheduled for carbon dioxide laser resurfacing with retinol and hydroquinone, and our plasma-resurfacing patients with just hydroquinone. To the author's knowledge, no studies have been done using preoperative retinols for patients being treated with nitrogen plasma. After the procedure we usually wait 30 days before restarting retinols in both groups.

Infection Prophylaxis

All patients receiving perioral treatments are started on valacyclovir, 1 g daily for 7 days starting on the day of treatment for herpes simplex prophylaxis. All patients are placed on bacterial prophylaxis for 7

days starting on the day of treatment. Most patients receive cephalexin. Penicillin-allergic patients are given clindamycin or doxycycline.

Operative Technique

The delivery system consists of a tube that delivers nitrogen gas to a disposable hand piece that ignites the nitrogen gas, converting it to plasma just before it is delivered to the skin. The ignition takes place by vibrating a tungsten filament at an ultrahigh radiofrequency. An electronic key that controls hand-piece function is programmed for a limited number of treatments per hand piece. The FDA required this feature at the time of approval.

Sedation

Most of our patients are treated in our office under topical or topical plus subcutaneous local anesthesia. We have a Level 1 treatment facility, so we do not use any intravenous sedation. Patients who request sedation or general anesthesia have their procedures in the day-surgery unit of our hospital. Our office is located in the same building.

Skin preparation

- The original studies were done after hydrating the skin for 1 hour before the treatment. For this we use a topical anesthetic cream of benzocaine, tetracaine, and lidocaine compounded at a local compounding pharmacy, or commercially available 4% lidocaine cream.
- If the patient is under general anesthesia (eg, at the time of a facelift), the skin is hydrated with a petroleum ointment (Aquaphor).
- If treating without this period of hydration, the fluences are decreased about 30%.
- In the office, patients are given 5 to 10 mg of diazepam by mouth at the beginning of the 1-hour hydration period and 5 mg of oxycodone or a combination tablet of oxycodone, 5 mg and acetaminophen, 325 mg by mouth 15 minutes later.
- Topical anesthetic alone is usually sufficient for patients having treatments below 2 J (PSR 1; see later discussion).
- For higher-energy treatments (PSR 2 and PSR 2/3; see later discussion), regional blocks and direct infiltration are done with a total of 15 to 20 mL of 0.5% lidocaine, 1:200,000 epinephrine 10 minutes before the procedure. All 3 branches of the trigeminal nerve are blocked.
- Infiltration is also done directly along the superior edge of the entire length of the brow, the entire lower eyelid, the temple

just anterior to the temple tuft of hair, and an area along the jaw line and lateral cheek about 1.5 cm wide beginning just anterior to the sideburn and extending to the marionette crease.

- An upper dental block is placed intraorally, after applying a topical oral anesthetic gel (Hurricane).
- The most tender areas of the treatment are the temples, lateral cheeks, jaw line, upper hairline, and upper lip.
- Just before the treatment, we remove the topical anesthetic cream with a moist sponge and draw a grid on the skin with a temporary marker to help ensure that the energy is delivered uniformly (**Fig. 2**). Because this treatment is not chromophore dependent, the marker can be any color.

Skin care during treatment

- An important feature of this treatment is that the epidermis is purposely and carefully left intact. The intact epidermis acts as a biological dressing.

- During a treatment above 2 J per pulse, we frequently apply an ice pack to the first side of the face treated while treating the opposite side. A cooling device that blows cool air will also work well. The immediate cooling should not adversely affect the efficacy of the treatment.

Skin care after treatment

- We apply a petroleum-based ointment (Aquaphor) immediately after the treatment along with a cool gel mask. The petroleum ointment acts as a heat sink by itself, and the gel mask seems to facilitate the process.
- The skin is protected from the mask by soft gauze. The mask is left in place until it is again room temperature, after about 30 minutes.
- Our music or the patient's own music also helps with pain control at this point.
- The petroleum ointment is reapplied and the patient is discharged. Most patients report that the only pain is like intense sunburn, which is largely gone within 1 to 4 hours.

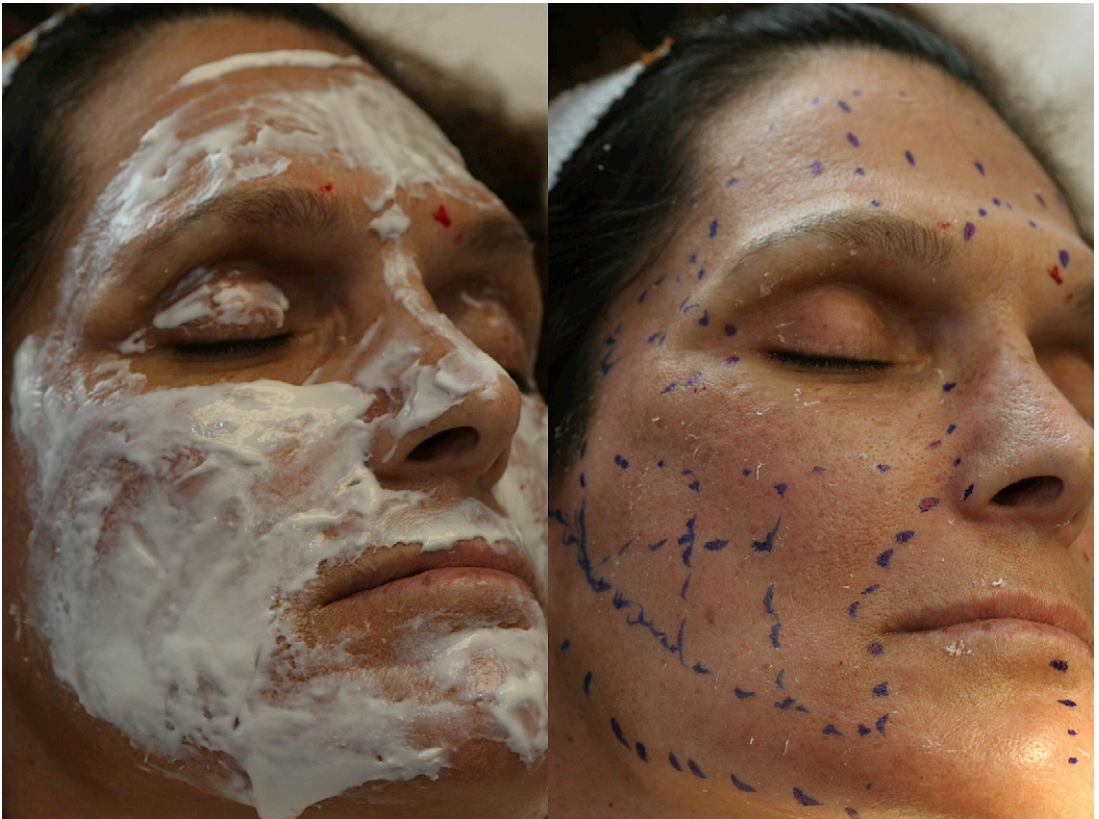

Fig. 2. Topical anesthetic cream and grid to guide the treatment. (Courtesy of Energist Group, Nyack, NY & Swansea, Wales, UK; with permission.)

Posttreatment pain relief

- Some patients take oxycodone the evening of the procedure and some just acetaminophen, 650 to 1000 g. Usually no pain medication is needed after the first day. If a patient complains of significant pain the next day, we observe them more closely for a herpes simplex infection. Postoperatively this procedure should not be very painful.

Treatment protocols

There is a specific nomenclature for the various treatment protocols (**Fig. 3**):

- PSR 1: 1 to 2 J per pulse in a single pass
- PSR 2: 2 to 4 J per pulse in a single pass
- PSR 3: 2 to 4 J per pulse in a double pass
- PSR 2/3: PSR 2 and PSR 3 to different parts of the face.

The choice of treatment protocol depends on the patient's aesthetic goals, the amount of downtime the patient will tolerate, and perceived or actual Fitzpatrick skin type.

Protocol for Fitzpatrick types 1 to 3

We commonly treat Fitzpatrick skin types 1 to 3 with 3.3 to 3.8 J per pulse in a single or double pass (PSR 2/3). In areas of thin skin over bony prominences, such as the superior orbital rim, temple, upper eyelids, jaw line lateral to the jowl, and forehead, we typically do a single pass. The glabella, lower eyelids, nose, and the rest of the face typically tolerate a double pass. The neck and chest are treated in a single pass below 2.0 J.

Protocol for Fitzpatrick type 4

We treat patients with Fitzpatrick skin type 4 or some Native American lineage with a significant propensity for hyperpigmentation in a series of lower-energy treatments of 1.3 to 2 J per pulse in

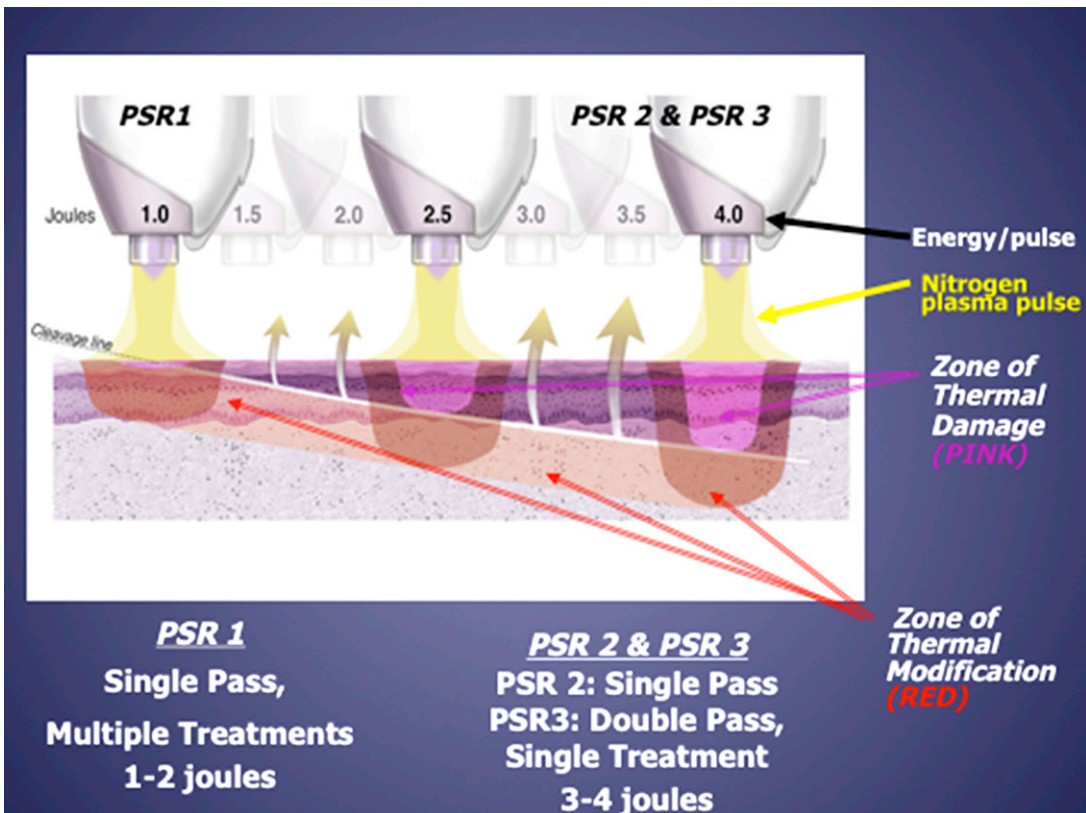


Fig. 3. Higher energy promotes more depth of penetration of the zones of thermal damage and thermal modification, lowering the line of cleavage deeper into the dermis. (Courtesy of Energist Group, Nyack, NY & Swansea, Wales, UK; with permission.)

a single pass (PSR 1) spaced 4 to 6 weeks apart. These patients are most commonly being treated for diffuse hyperpigmentation, and require 2 to 4 treatment sessions. If, after the first 2 low-energy treatments there is no evidence of postinflammatory hyperpigmentation, we may do the third treatment at 2.5 to 3.0 J. We have sometimes seen some postinflammatory hyperpigmentation with the higher-energy third treatment, but we have always been able to clear this relatively quickly with a 4% hydroquinone regimen (see the patient in Fig. 17).

In the PSR-3 protocol, the second pass is generally done at right angles to the first pass, to assure maximum coverage without gaps of untreated skin (Fig. 4).

Postoperative Period

We see all our patients 12 to 24 hours after the treatment, before they wash their face for the first time after the treatment.

- It is important to make sure that the patient is generously applying the petroleum ointment. During the week after the procedure, the petroleum ointment is important for protecting the treated epidermis from premature peeling that could lead to unwanted scar formation. Application is done best with a vinyl examination glove.
- Face washing begins 24 hours after the treatment. We encourage the patient to wash very gently with a mild face wash (eg, Cetaphil) 3 times a day, and let lukewarm water run over the face either in the shower or by splashing from the sink. A clean spray bottle filled with warm water also works nicely. We are very specific about avoiding rubbing of the face.
- The petroleum ointment is applied liberally after each face wash.
- It is important to be very realistic with the patient about the amount of time required away from work. The epidermis very

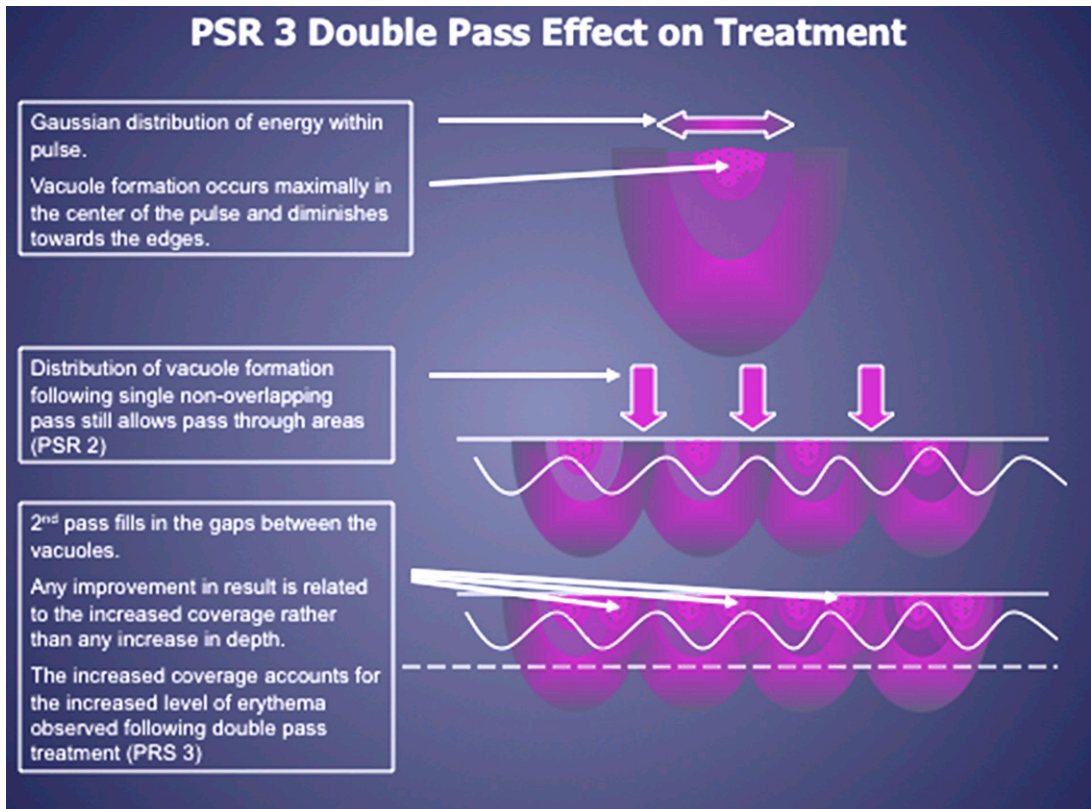


Fig. 4. Effect of a double pass with energies greater than 2 J (plasma skin regeneration [PSR] 3). (Courtesy of Energist Group, Nyack, NY & Swansea, Wales, UK; with permission.)

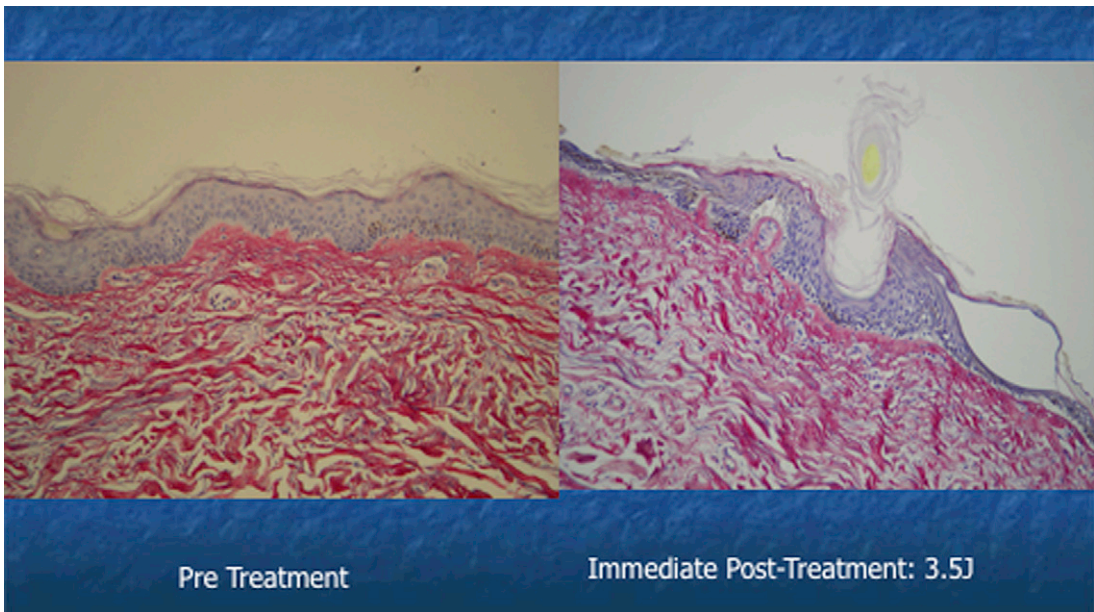


Fig. 5. Immediate effect is heating of the dermis and epidermis, leaving the epidermis intact. Only smoke is seen from heating the hairs. (Courtesy of Energist Group, Nyack, NY & Swansea, Wales, UK; with permission.)

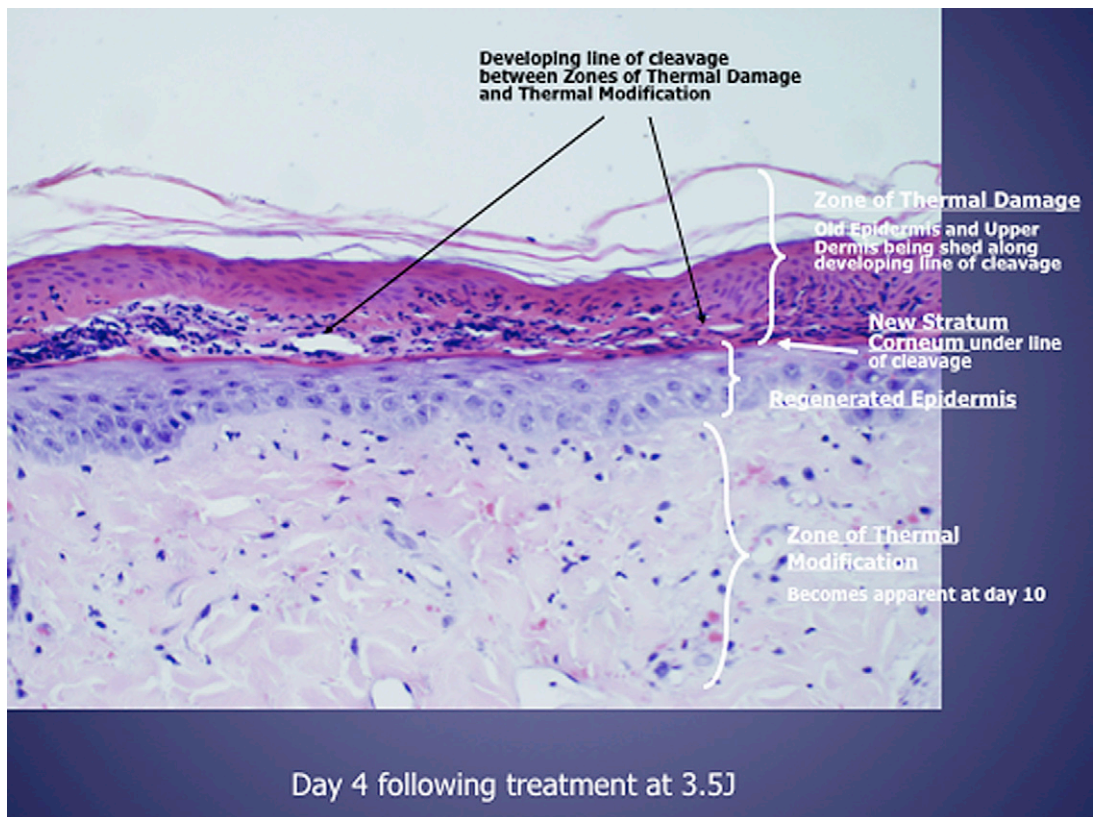


Fig. 6. Histology. Day 4 after a Portrait nitrogen plasma treatment with 3.5 J. Separation of old epidermis from the new epidermis, along the line of cleavage that forms between the zones of thermal damage and thermal modification, begins. This process usually lasts until day 6 or 7. (Courtesy of Energist Group, Nyack, NY & Swansea, Wales, UK; with permission.)

predictably will begin to shed in 4 to 5 days and be completely regenerated in 7 to 8 days. With energies below 2 J, it in fact can be 2 to 4 days more.

- If there is no significant erythema, we start a mild moisturizer without any glycolic or lactic acids once the old epidermis has peeled.
- The patient also resumes sunscreen (SPF 45 or above) and may apply a mineral make-up the next day. Mild moisturizers combined with sunscreen work very well also.
- If the patient has more erythema than is typical, we prescribe desonide ointment or cream twice a day for 7 to 10 days. This short course of low-concentration corticosteroid should not adversely affect neocollagenesis.

RESULTS OF SKIN PLASMA RESURFACING *Evidence-Based Medicine: Histologic Changes Vary with the Amount of Energy Delivered and How It Is Delivered*

There are very specific histologic changes noted with this device that govern the technique and influence the outcome of the treatment.^{6,7}

The Gaussian distribution of the energy in the skin creates a so-called inner zone of thermal damage and an outer zone of thermal modification (see **Fig. 3**). Skin biopsy studies show that the epidermis (including the stratum corneum) remains largely intact.^{6,7} There is no vaporization of tissue. The epidermis is left intact and allowed to slough on its own, usually beginning 4 to 5 days after the treatment (**Fig. 5**). In the meantime, it acts as a biological dressing. In the zone

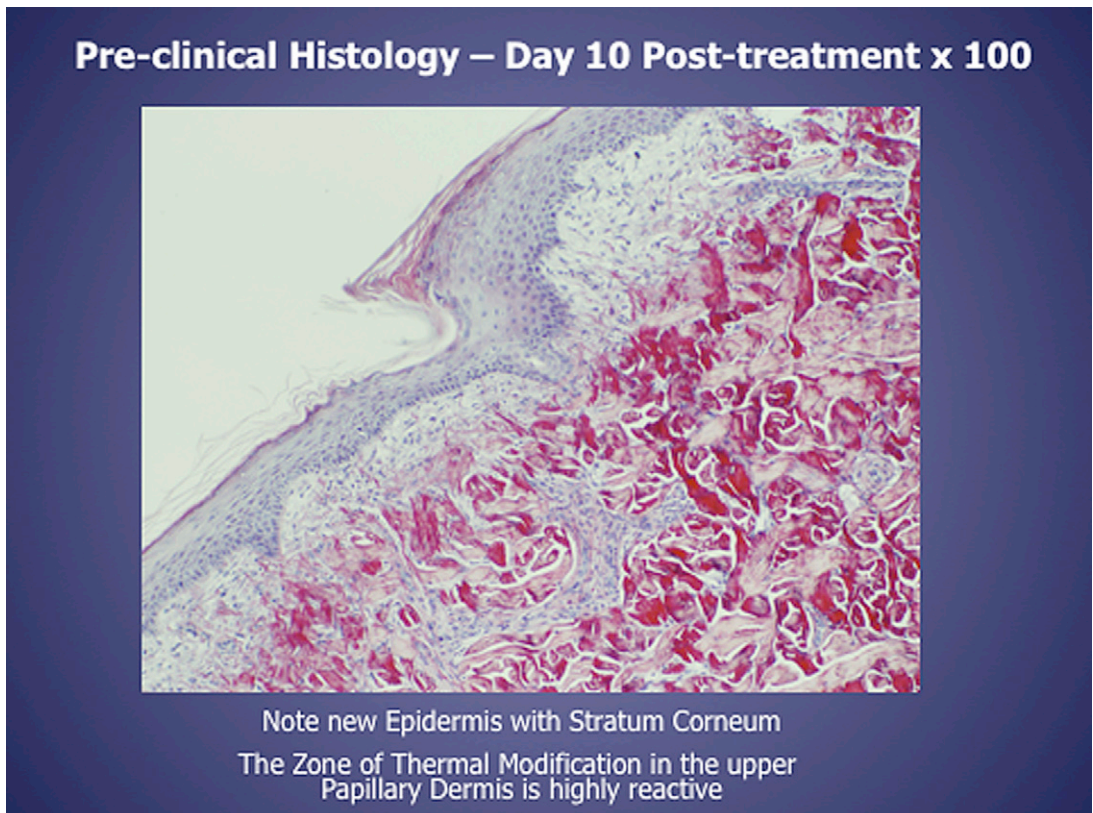


Fig. 7. There is a brisk reaction to the heat in the zone of thermal modification, shown here in the papillary dermis. Neocollagenesis is beginning. (Courtesy of Energist Group, Nyack, NY & Swansea, Wales, UK; with permission.)

of thermal modification, the heat penetration is sufficiently ablative to cause enough modification of the dermis to foster significant neocollagenesis. It can reach as deep as 500 to 600 μm .

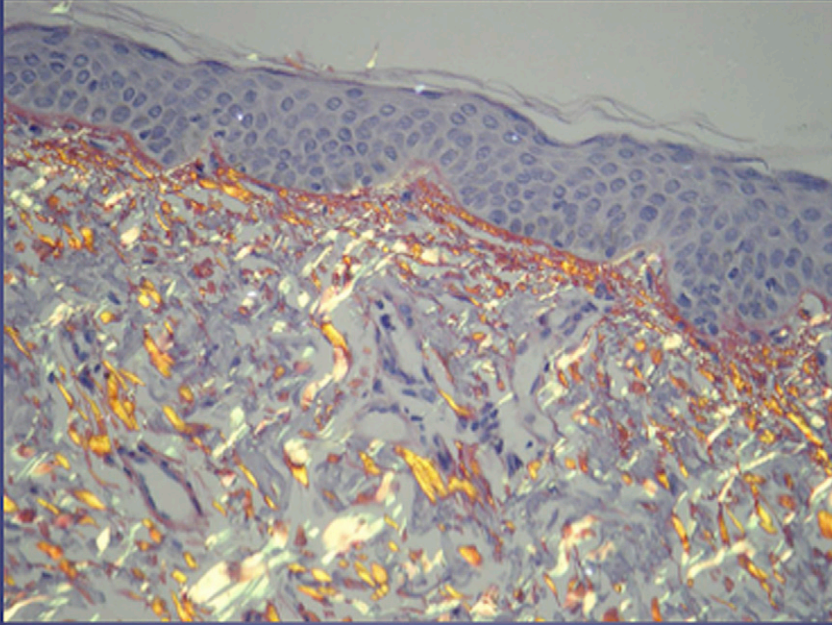
Higher energy promotes more depth of penetration of both zones. There is a predictable depth of affect with increases in energy (see **Fig. 3**). **Fig. 5** shows the very predictable histologic changes that occur in the epidermis and dermis with plasma energy applied over the 2-J break point between PSR 1 and the rest of the treatment techniques:

- At energies above 2 J there is a vacuole formation in some of the basal epidermal cells at the dermal-epidermal junction. These air-filled spaces are thought to insulate the dermis enough so as to permit the second pass of the PSR-3 protocol without heating the dermis to the point of irreparable damage or deeper penetration.⁶⁻⁸
- The second pass is done for uniform treatment, not deeper penetration.
- Increasing the energy increases the depth of zone of thermal damage and the zone of thermal modification, but a second pass at energies higher than 2 J simply fills in the gaps between previously treated spots. It gives a more uniform treatment but not a deeper treatment (see **Fig. 4**).
- By about day 4 after the treatment, a line of skin cleavage forms between a newly, regenerated epidermis and old epidermis (**Fig. 6**).
- By days 8 to 10 there has been complete remodeling of the epidermis, and neocollagenesis has begun (**Fig. 7**). A fully regenerated epidermis with residual activity in basal layer is present. In the zone of thermal modification in the deep dermis there is intense fibroblast activity and neovascularization, regenerating the reticular architecture of

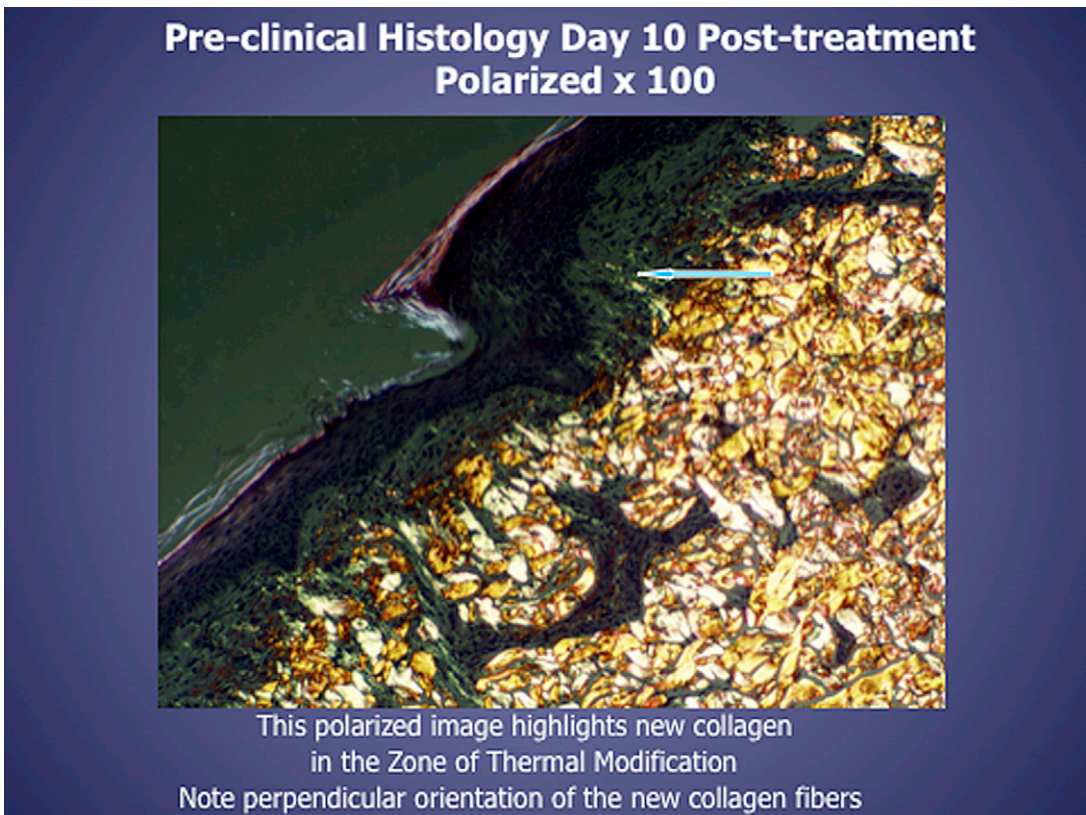

Fig. 8. Same biopsy of skin as in **Fig. 7**. Here the polarized image shows the neocollagenesis. Much of the new collagen in the dermis is perpendicularly oriented. (Courtesy of Energist Group, Nyack, NY & Swansea, Wales, UK; with permission.)

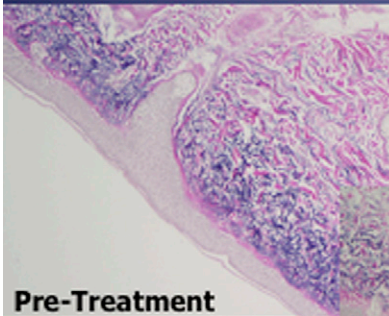
Biopsies: Neo-collagenesis at Day 90 (mag. x 400)



Zone of New Collagen underlying the D/E junction

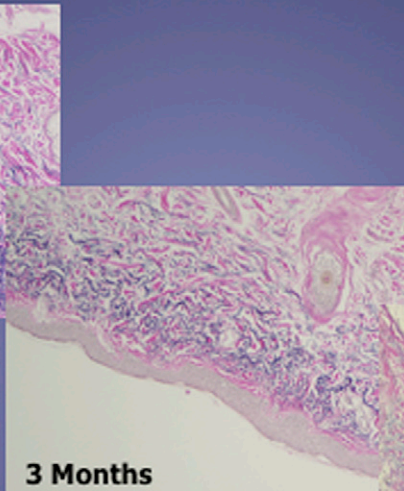
Fig. 9. Plentiful neocollagenesis at 90 days, much of it perpendicularly oriented. D/E, dermal-epidermal. (Courtesy of Energist Group, Nyack, NY & Swansea, Wales, UK; with permission.)

Clinical Skin Regeneration at 1 Year



Pre-Treatment

Solar elastosis (blue/black) with narrow, well-marked collagen band at the flattened DE junction, the Grenz Zone

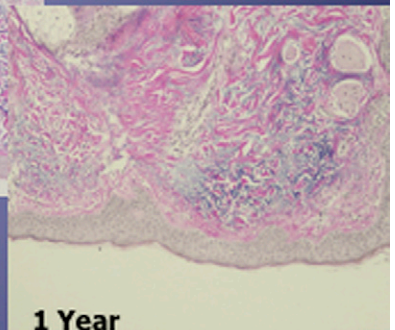


3 Months

30% reduction of the depth of elastosis with a widening of the collagen band at the DE junction as new collagen is laid down

1 Year: Continued reduction in amount & density of elastosis with in-growth of regenerated reticular architecture

Further widening of the new collagen at the DE junction with a healthier undulating appearance



1 Year

Fig. 10. Collagen neogenesis and reduction of solar elastosis continues for up to 1 year. DE, dermal-epidermal. (Courtesy of Energist Group, Nyack, NY & Swansea, Wales, UK; with permission.)

the dermis. The zone of thermal modification in the upper papillary dermis, in particular, is highly reactive.

- **Fig. 8** is a polarized image that highlights new collagen in the zone of thermal modification. Note the normal perpendicular orientation of the new collagen fibers in this illustration.
- By 90 days, there is a very significant zone of neocollagenesis at the dermal-epidermal junction (**Fig. 9**).⁶⁻⁹
- The improvements continue for up to 1 year (**Fig. 10**).

- **Figs. 11** and **12** show the typical clinical progression of healing.

Choosing the Right Patient

In our experience the best candidates for this technology are patients with:

- Wrinkles Grade 1 through 3 (Wrinkle Severity Rating Scale 1–5)
- Hyperpigmentation
- Fitzpatrick skin types 1 through 4.

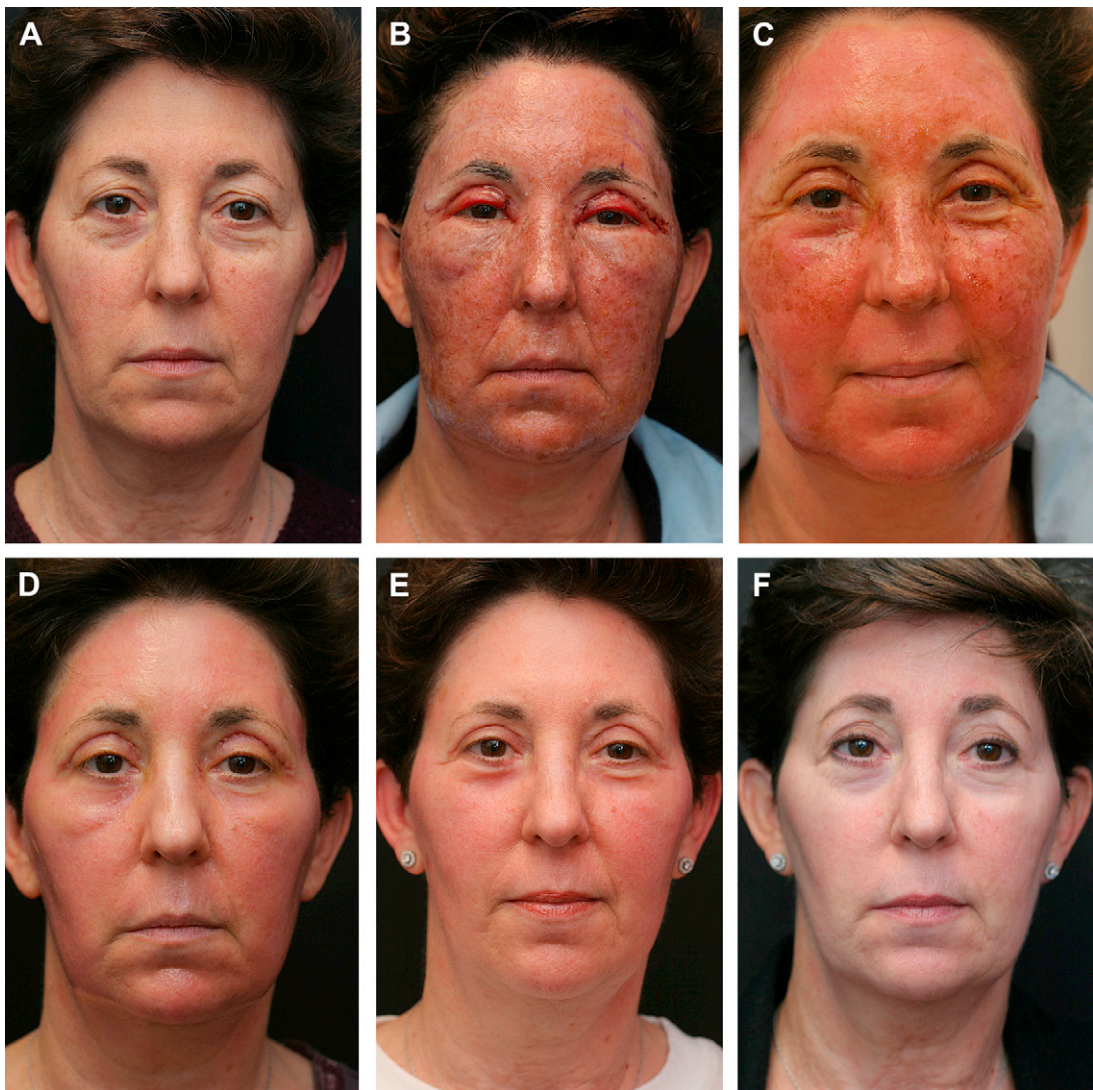

Fig. 11. Healing progression in a 60-year-old woman, Fitzpatrick 3, PSR 2/3 at 3.3 to 3.6 J. (A) Before treatment. (B) 24 hours, (C) 4 days (starting to peel), (D) 8 days, (E) 23 days, and (F) 17 months after treatment. Early post-operative upper eyelid swelling is from simultaneous upper lid blepharoplasty.

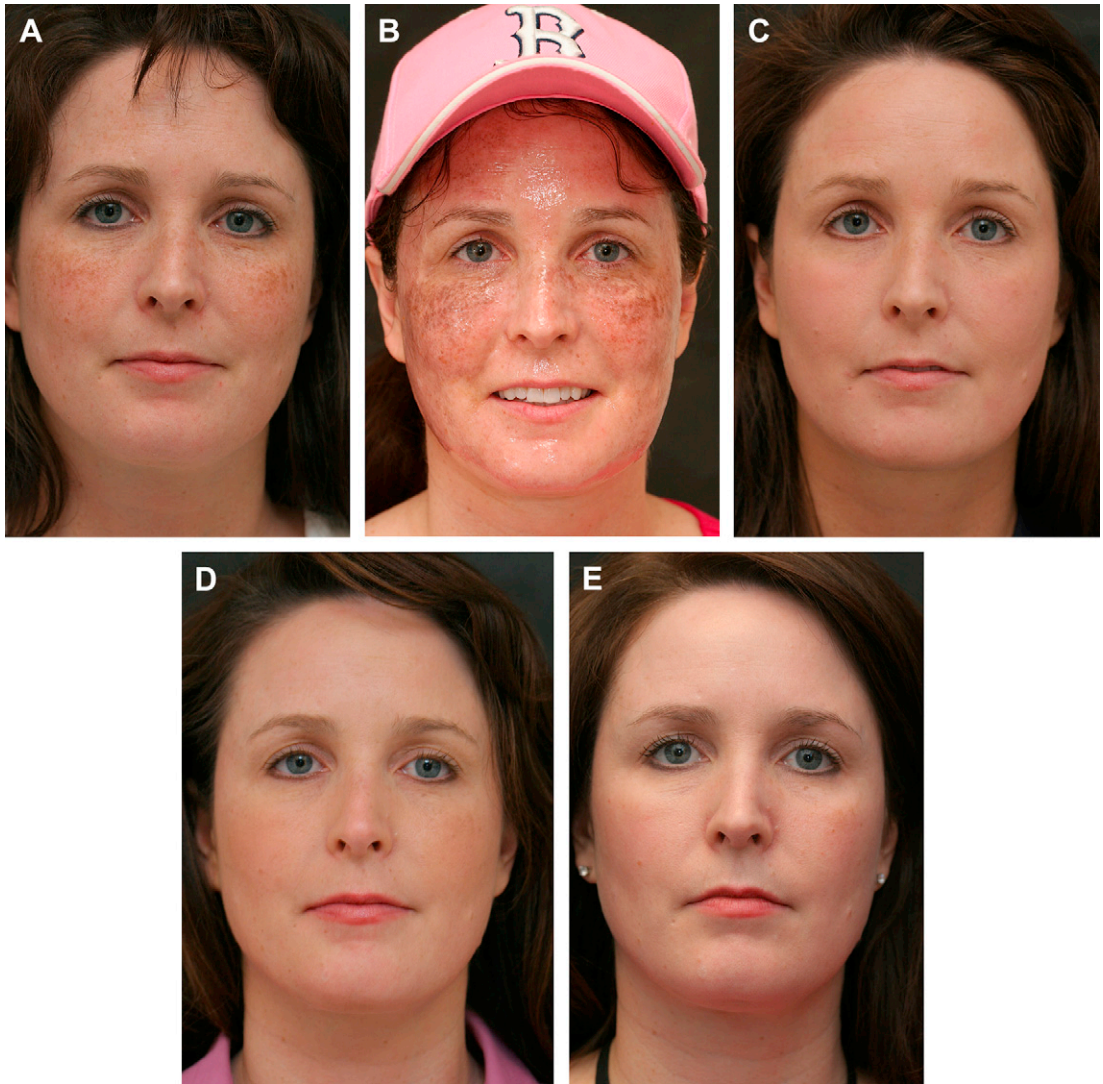

Fig. 12. Healing progression in a 34-year-old woman. Fitzpatrick type 3. PSR 2/3 at 3 J. (A) Preoperatively, (B) immediately after the treatment, (C) 9 days after treatment, (D) 1 month after treatment, and (E) 7 months after treatment.

For maximum wrinkle reduction, we use a fractionated carbon dioxide laser (Lumenis UltraPulse; Lumenis, Yokneam, Israel) in multiple passes so as to achieve significant ablation. Downtime is usually 8 to 10 days.

Who Not to Treat

The efficacy of plasma resurfacing depends on the ability of the skin to produce new collagen; this rules out most patients in their late 60s and beyond. There is little or no improvement in these

patients. While shorter downtime and potentially lower cost of a plasma treatment often appeals to patients in their late 60s or early to late 70s, it is usually not the right choice.

Who is a Reasonable Candidate for Plasma Resurfacing?

Figs. 13–17 show typical results for well-selected patients. The only make-up permitted for the photos is lipstick and eyeliner. Only the patient in **Fig. 12** has less than 1 year of follow-up.

The woman in **Fig. 13** was 53 years old at the time of her treatment. She has Fitzpatrick type-3 skin and was treated with the PSR-3 protocol at 3.3 to 3.5 J. Like many of our patients, this patient has been maintained on Obagi NuDerm (Obagi, Long Beach, CA) with tretinoin since 3 months postoperatively. On more than one occasion, strangers have stopped her in stores to comment on the clarity of her skin. At 14 months after the procedure she had a superficial musculoaponeurotic system flap facelift and transconjunctival lower lid blepharoplasty with fat transposition. She receives botulinum toxin to the glabella and forehead, and calcium hydroxyl apatite to the melolabial creases and midface periodically. The postoperative photos shown are at 1 year and 44 months. At 44 months, there is significant persistence of overall, uniform improvement in skin color and texture along with a persistent loss of periocular and malar rhytids.

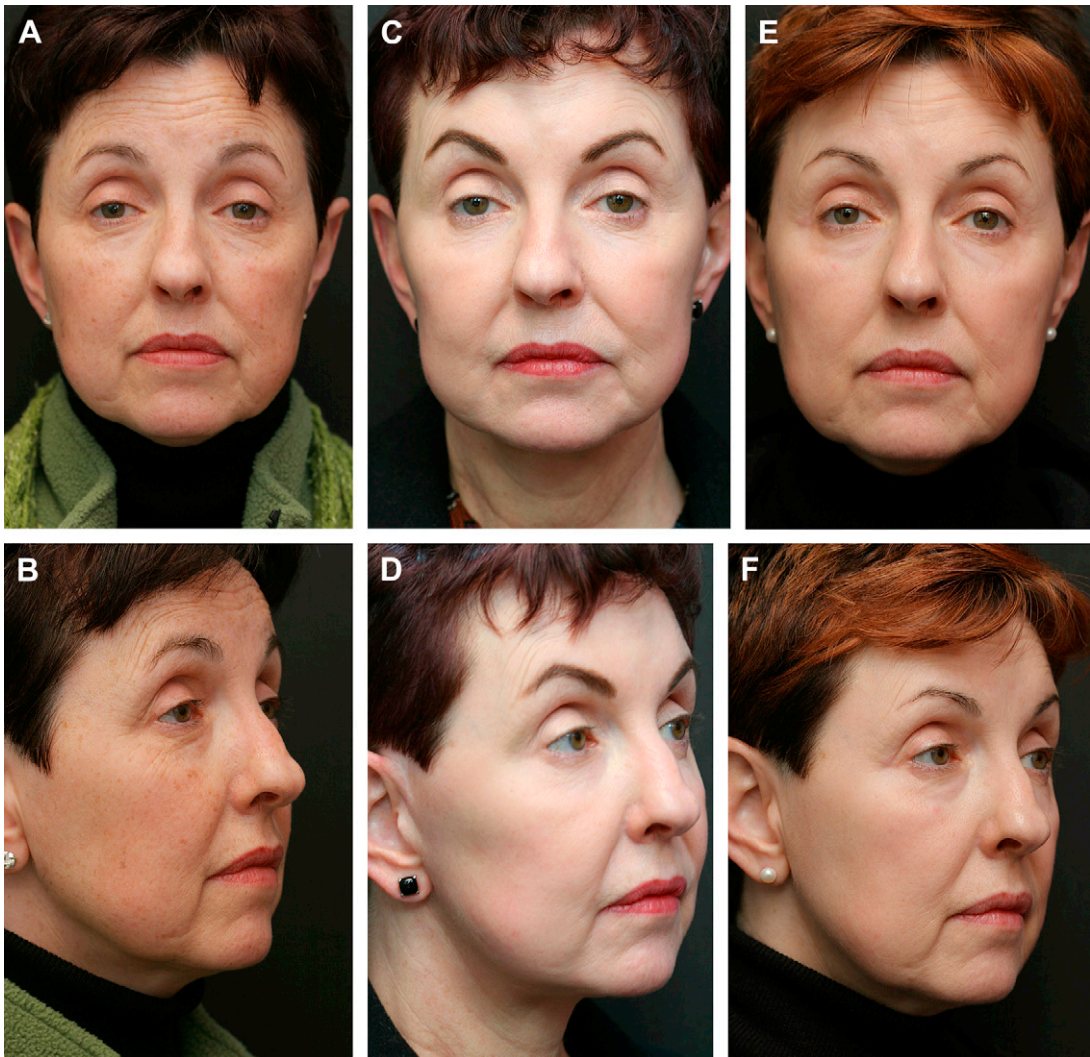

Fig. 13. A 53-year-old woman, Fitzpatrick type 3, PSR 2/3 at 3.3 to 3.6 J. (A, B) Before treatment, (C, D) 1 year after treatment, and (E, F) 44 months after treatment. (Facelift and lower lid blepharoplasty was performed 14 months postoperatively.)

The woman in **Fig. 14** was 52 years old at the time of her treatment. She has Fitzpatrick type-3 skin and was treated with the PSR-2/3 protocol at 3.2 to 3.4 J. She had a single pass on the upper eyelids at 3.2 J and a double pass on the lower eyelids and crow's foot area at 3.2 J. She does not use any products recommended by us. The postoperative photos are at 18 months and 5 years. The images focus on the results around her eyes. In this case, there was some contracture of the excess skin of her upper eyelids that persists even at 5 years.

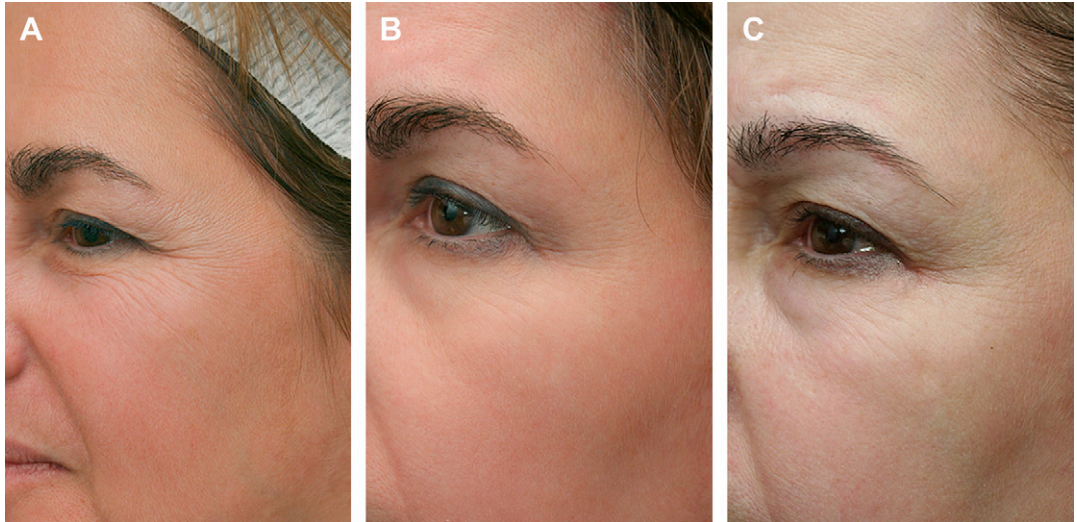


Fig. 14. A 52-year-old woman, Fitzpatrick type 3, PSR 2/3 at 3.2 J to upper and lower eyelids and crow's foot area. (A) Before treatment, (B) 18 months after treatment, and (C) 5 years after treatment.

Fig. 15 shows a patient with Fitzpatrick type-2 skin who was 35 years old at the time of her treatment. She initially had just her lower eyelids and crow's foot treated at the time of a transconjunctival lower lid blepharoplasty with fat transposition. She decided 1 year later to have her whole face treated. The entire face was treated, including retreatment of the lower lids. The postoperative photo is 1 year after that second treatment. She does not use a daily skincare regimen recommended by us. She does use a high-SPF sunscreen. There is very good improvement in the overall uniformity of color and texture of the skin.

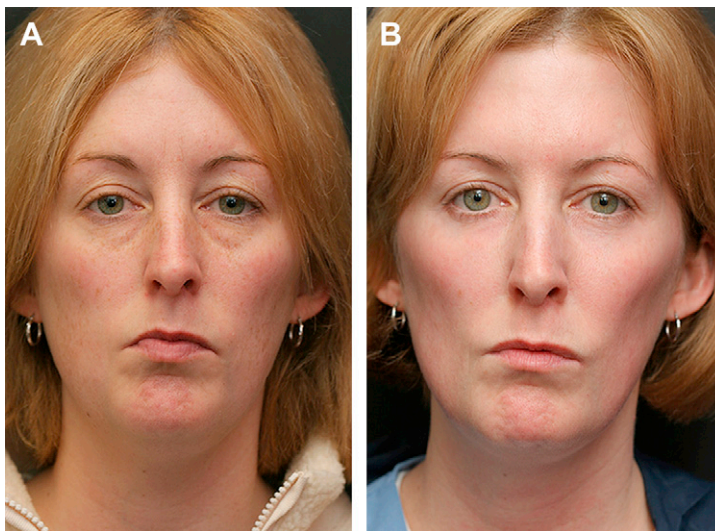

Fig. 15. (A, B) A 35-year-old woman, Fitzpatrick type 2, PSR 3, 3.3 to 3.4 J. Lower lids and crow's feet were treated at the time of transconjunctival lower lid blepharoplasty with fat transposition. The rest of the face was treated about 1 year later and original areas were also re-treated. The postoperative photo (B) was taken 1 year after that second treatment.

The patient in **Fig. 16** was 46 years old at the time of her treatment. She has Fitzpatrick type-2 skin was treated with the PSR-2/3 protocol at 3.3 to 3.5 J. She is maintained on the Obagi CRx system without tretinoin. The postoperative photos are at 1 year and 2 years. At 2 years there is very good persistence of overall improvement in skin color and texture, but the patient would probably benefit from a touch-up treatment of the periocular rhytids and a lower lid blepharoplasty with fat transposition.

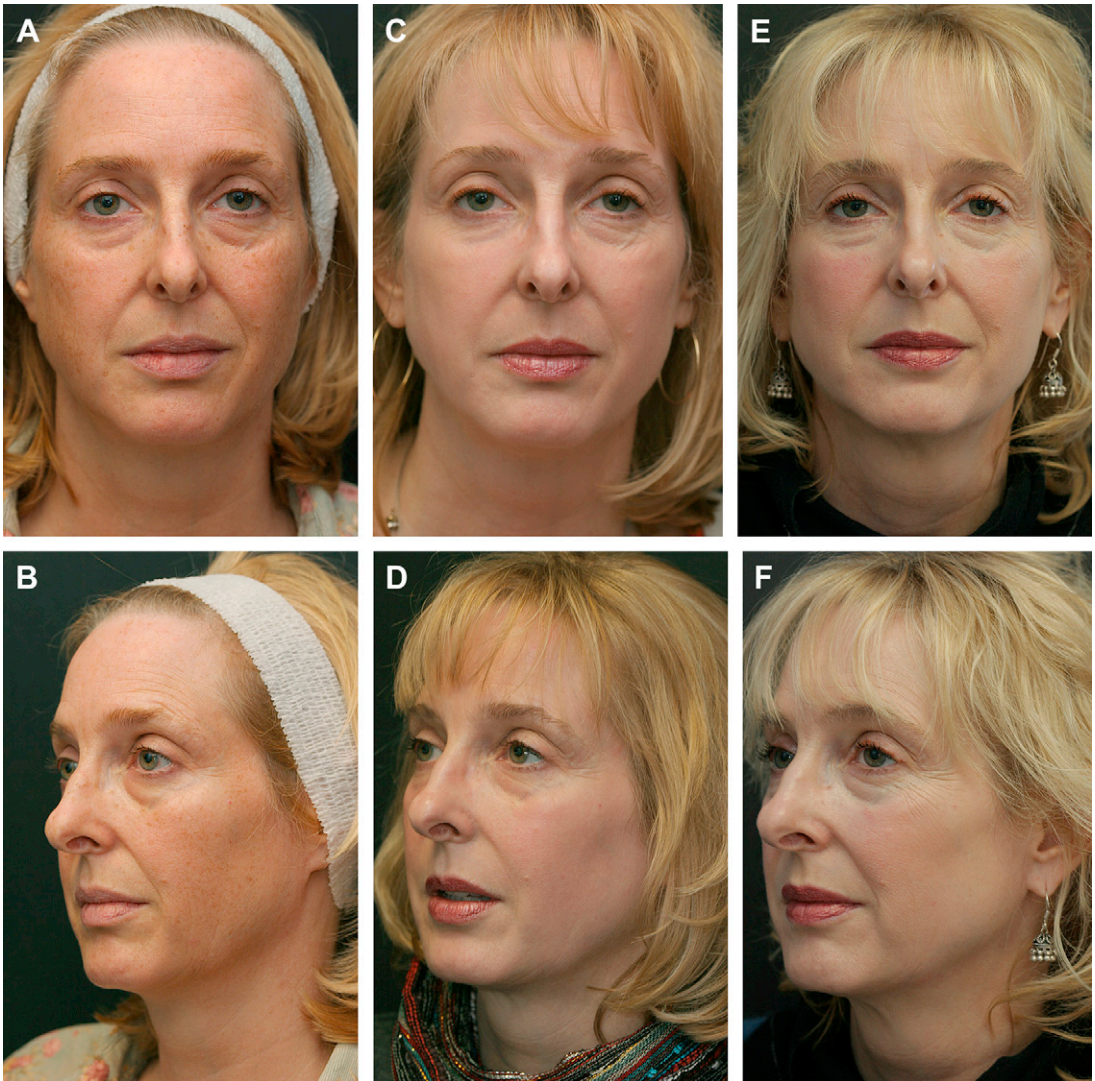

Fig. 16. A 46-year-old woman, Fitzpatrick type 2, PSR 2/3, 3.3 to 3.5 J. (A, B) Before treatment, (C, D) 1 year after treatment, and (E, F) 2 years after treatment.

Fig. 17 shows a patient of Portuguese lineage with Fitzpatrick type-4 skin. She was 53 years old at the time of her treatments. Because of her darker skin type, we planned a series of lower-energy treatments (PSR 1) 1 month apart. She was pretreated with 4% hydroquinone (Obagi Clear) for 6 weeks before the first treatment, and starting the day after peeling ended in between treatments. The 3 treatments were at 1.3, 1.6, and 1.9 J, respectively. Four months after the last PSR-1 treatment, we decided to do a fourth treatment at 3.0 J with the PSR-2/3 protocol for further overall lightening of her skin. While she saw overall improvement in the quality and texture of her skin along with a modest generalized decrease in hyperpigmentation, she wanted a more profound decrease in the hyperpigmentation. The patient wanted the color of her skin to be as close as possible to that when she was a teenager and young adult. One month after this high-energy treatment she developed some transient postinflammatory hyperpigmentation of her lower eyelids, which resolved within 30 days by just staying on the same hydroquinone preparation she had been using. The postoperative photos are at 9 months (after the initial 3 PSR-1 treatments) and at 3 years after the start of all of the treatments. Since the procedure she has been maintained on the Obagi CRx system with tretinoin. At 3 years, she maintains a significant improvement in overall uniformity of color and skin texture.

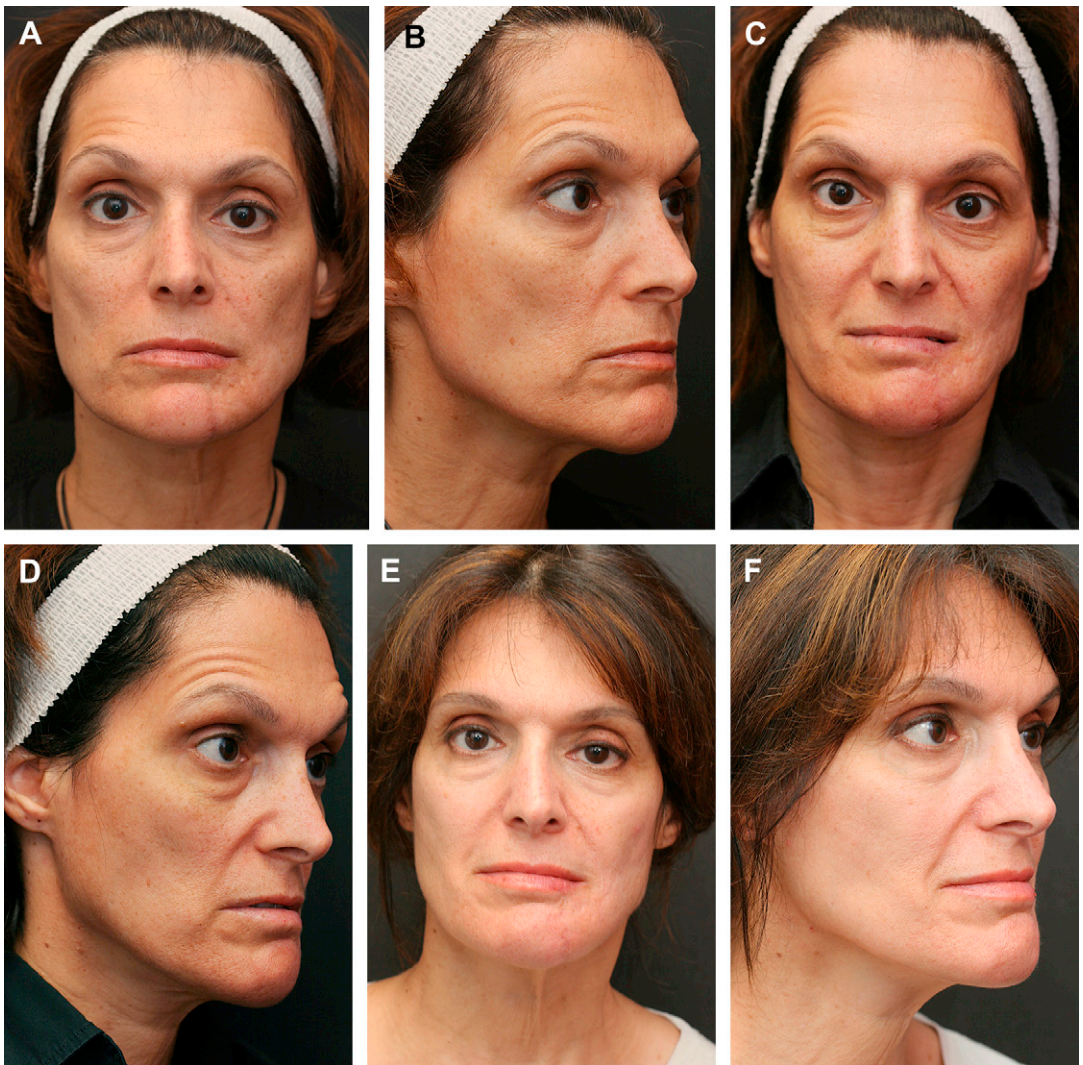

Fig. 17. A 53-year-old woman with Fitzpatrick type-2 skin (A, B) was treated initially with a PSR-1 regimen of 3 treatments 1 month apart at 1.3, 1.6, and 1.9 J, respectively. Four months later she was treated with a PSR-2/3 regimen at 3.0 J. The first postoperative photos (C, D) show the appearance after the initial 3 PSR-1 treatments. The second postoperative photos (E, F) were taken 3 years after the start of all treatments.

Fig. 18 shows treatment of a benign lentigo. The 53-year-old man with Fitzpatrick type-3 skin is a part-time farmer who used little sunscreen presenting at our office. Biopsy showed a benign lentigo. The area was treated once at 3.5 J with a double pass (PSR 3). The postoperative photo is at 2 years 9 months. He now uses high-SPF sunscreen as his only skin regimen, when “on the tractor.”

PLASMA RESURFACING IS A VERY USEFUL TECHNOLOGY

Nitrogen plasma skin regeneration is a skin-resurfacing technique that offers excellent improvement of mild to moderate skin wrinkles and excellent overall skin rejuvenation. It also provides excellent improvement in uniformity of skin color and texture in patients with hyperpigmentation with Fitzpatrick skin types 1 through 4.

Severity of Wrinkles Treated with Plasma

Since July 2006 we have used plasma skin resurfacing and find it a very efficacious technology. We position this technology between radiofrequency skin tightening for fine lines only (Pellevé) and fractionated and nonfractionated carbon dioxide laser resurfacing for deep wrinkles. We use the radiofrequency treatments for patients of all Fitzpatrick skin types with no hyperpigmentation and wrinkle severity grade 1 to 2.

We recommend plasma for patients with wrinkle severity grades 1 through 3 and who most commonly have concomitant hyperpigmentation. We also recommend it for moderate pore reduction. In general, a plasma treatment does not penetrate the skin as deeply as a fully ablative carbon dioxide laser treatment (500–600 μm versus up to 450 μm

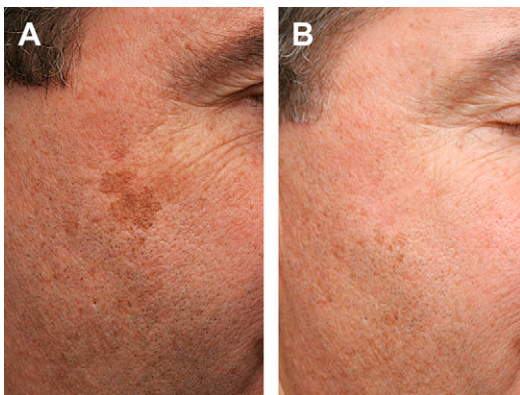


Fig. 18. Benign lentigo treated with double pass at 3.5 J (PSR 3). (A) Before treatment. (B) Two years 9 months following the procedure.

to 1 mm). We have found plasma resurfacing disappointing for deep upper lip rhytids.

We use the fractionated and nonfractionated carbon dioxide laser for patients with wrinkle severity grade 1 through 5 with or without hyperpigmentation. The laser is also our preferred modality for treating upper lip rhytids grades 2 to 5.

Risk of Hypopigmentation and Postinflammatory Hyperpigmentation

We have not seen any hypopigmentation or permanent postinflammatory hyperpigmentation with plasma. We are very proactive with hydroquinone in all skin types. Although perhaps not necessary with Fitzpatrick skin types 1 and 2, this preparation does allow us to maximize the energy delivered. Most of the patients we treat with Fitzpatrick type-3 skin are seeing us at least partially because of their hyperpigmentation, so this prophylaxis seems to make sense. In patients with Fitzpatrick type-4 skin, the hydroquinone is absolutely necessary. As illustrated with the patient in **Fig. 15**, type-4 skin requires a protocol of 3 to 4 low-energy treatments ranging usually from 1.3 to 2 J. If a patient with Fitzpatrick type-4 skin wants more dramatic reduction of wrinkles and hyperpigmentation, we may choose to do another treatment at 3 J or slightly above. The patient must be prepared to risk some postinflammatory hyperpigmentation, but this has never been known to be permanent. If the patient experiences any postinflammatory hyperpigmentation with the low-energy treatments, a last high-energy treatment will not be recommended.

Patient Expectations for Wrinkle Reduction

As with any minimally invasive procedure, setting realistic expectations is very important. If a patient wants maximum wrinkle reduction, the author recommends the carbon dioxide laser. Full ablation for severe wrinkles with the laser is more comfortable with sedation or general anesthesia, so cost can become a factor in the patient's decision. If the patient is more concerned about skin quality and color than wrinkles, plasma is recommended. Patients in their late 60s and older are not good candidates for plasma resurfacing, as they will not mount a significant enough neocollagenesis to see acceptable results.

Qualitative Results of Plasma Resurfacing

From a completely subjective point of view, the quality, texture, and uniformity of color we see with plasma are often better than with the carbon dioxide laser. Such comparison photos are not presented here, but could become the subject of a separate

study with blinded observers. We have not seen any of the hypopigmentation with plasma that can be a rare sequela (in our hands) of deep carbon dioxide laser resurfacing. In cases where the skin has been lightened, it has been uniformly lightened and consistently closer to the color of the patient's facial skin as a teenager (confirmed by patient affirmation and younger photos) and the less sun-exposed skin on the patient's body.

REFERENCES

1. Specifications of Lumenis UltraPulse® laser. Available at: <http://www.aesthetic.lumenis.com/pdf/FINALCO2FamilyBrochure23Mar11.pdf>. Accessed November 6, 2011.
2. Lukac M, Perhavec T, Nemes K, et al. Ablation and thermal depths in VSP Er:YAG laser skin resurfacing. *Journal of the Laser and Health Academy* 2010(1). Available at: http://www.laserandhealthacademy.com/media/objave/academy/priponke/ablation_and_thermal_depths_in_vsp_eryag_laser_skin_resurfacing.pdf. Accessed November 6, 2011.
3. Rahman Z, Alam M, Dover JS. Fractional laser treatment for pigmentation and texture improvement. *Skin Therapy Lett* 2006;11(9):7–11.
4. Heinlin G, Isbary G, Stolz W, et al. Plasma applications in medicine with a special focus on dermatology. *J Eur Acad Dermatol Venereol* 2011;25(1):1–11.
5. Kilmer S, Semchyshyn N, Shah G, et al. A pilot study on the use of a plasma skin regeneration device (Portrait® PSR³) in full facial rejuvenation procedures. *Lasers Med Sci* 2007;22(2):101–9.
6. Fitzpatrick R, Bernstein E, Iyer S, et al. A histopathologic evaluation of the plasma skin regeneration system (PSR) versus a standard carbon dioxide resurfacing laser in an animal model. *Lasers Surg Med* 2008;40(2):93–9.
7. Tremblay JF, Moy R. Treatment of post-auricular skin using a novel plasma resurfacing system: an in vivo clinical and histologic study [abstract]. *Lasers Surg Med* 2004;34(Suppl 16):25.
8. Forster KW, Moy RL, Fincher EF. Advances in plasma skin regeneration. *J Cosmet Dermatol* 2008;7(3):169–79.
9. Bogle MA, Arndt KA, Dover JS. Evaluation of plasma skin regeneration technology in low-energy full-facial rejuvenation. *Arch Dermatol* 2007;143(2):168–74.
10. Alster T, Sailesh K. Plasma skin resurfacing for regeneration of neck, chest, and hands: investigation of a novel device. *Dermatol Surg* 2007;33(11):1315–21.
11. Gonzalez MJ, Sturgill WH, Ross EV, et al. Treatment of acne scars using the plasma skin regeneration (PSR) system. *Lasers Surg Med* 2008;40(2):127.
12. Elsaie ML, Kammer JN. Evaluation of plasma skin regeneration technology for cutaneous remodeling. *J Cosmet Dermatol* 2008;7(4):309–11.
13. Groff WF, Fitzpatrick RE, Uebelhoer S. Fractional carbon dioxide laser and plasma kinetic skin resurfacing. *Semin Cutan Med Surg* 2008;27(4):239–51.
14. Holcomb D, Kent KJ, Rousso DE. Nitrogen plasma skin regeneration and aesthetic facial surgery: multicenter evaluation of concurrent treatment. *Arch Facial Plast Surg* 2009;11(3):184–93.