

Facial Acne and Fine Lines

Transforming Patient Outcomes With Plasma Skin Regeneration

Matthew J. Potter, MRCS,* Richard Harrison, MRCS,* Alex Ramsden, MRCS,*
Bernard Bryan, MIOT,† Philip Andrews,† and David Gault, FRCS*

Background: A novel device for skin rejuvenation has been developed and tested. The device converts a stream of nitrogen into a plasma of ionized gas, which ablates surface tissue in a controlled manner.

Methods: Eleven patients were followed up for 6 months. The results were assessed objectively using skin molds to measure skin irregularity, as well subjectively using patient- and doctor-assessed parameters.

Results: Plasma skin regeneration was shown to reduce fine line wrinkles by an average of 24% at 6 months ($P = 0.005$, Mann-Whitney rank sum test) and to improve acne scarring by 23% at 6 months ($P = 0.001$, Mann-Whitney rank sum test).

Conclusions: The main benefit of this system was that the patients had minimal erythema lasting only 1–6 days and no pigmentary changes. This is therefore a device with proven efficacy and limited morbidity.

Key Words: plasma skin regeneration, facial rejuvenation, facial acne, fine lines

(*Ann Plast Surg* 2007;58: 608–613)

Skin aging and scarring are cosmetic disfigurements, which may cause psychologic problems and prompt patients to seek advice about treatment. Solar damage of the skin leads to epidermal abnormalities, such as lentigenes, actinic kera-

tos, and the degeneration of collagen, which results in the formation of rhytids and telangiectasias. A variety of different treatments have been used for the rejuvenation of sun-damaged skin, including topical retinoids, bleaching agents, chemical peeling, dermabrasion, and lasers. In addition, many different types of scars can be improved by excision, dermabrasion, soft tissue augmentation materials, chemical peeling, and lasers, either alone or in combination.

Both carbon dioxide and erbium YAG lasers have proved effective in skin rejuvenation but have significant side effects such as scarring and pigmentary alteration.¹ Laser complications may also be transient: erythema, pruritus, milia formation, and acneiform pustules. Hypopigmentation rates may reach 16%² and may worsen with time. This complication is permanent, the potential mechanism being a deep follicular melanocyte injury.

Postoperative long-lasting erythema following laser treatment is a major drawback and is commonly responsible for the increased laser downtimes. Focal erythema may precede hypertrophic scarring or permanent hypopigmentation if it persists for 6–12 months. Although the resulting scars may be improved by silicon gel treatment, potent topical steroids, intralesional steroids, 5FU, and flash-lamp pulsed dye laser, they constitute a considerable morbidity.

The ideal rejuvenation tool would therefore aim to avoid these side effects yet provide long-term benefit with a minimal postoperative recovery period and a rapid return to normal activities. Plasma skin regeneration (PSR) is an FDA-approved device developed to be such a tool. It is not a light-based or a radio-frequency treatment system but delivers energy to the patient's tissue by plasma, the fourth state of matter, in which electrons are stripped from atoms to form ionized gas.

PSR

PSR achieves controlled tissue ablation using plasma pulses created by passing ultrahigh radio-frequency (RF) energy through nitrogen gas. The plasma generated is directed onto the patient's skin through an exit nozzle (Fig. 1, upper). When the plasma impacts on skin, released energy causes localized and rapid heating. Plasma generation is pulsed so that a known amount of energy is delivered to a predetermined tissue target. The user can select single-pulse and repeat-pulse operation, with the repeat rate adjustable from 1 to 4 Hz.

Received May 5, 2006, and accepted for publication, after revision, October 1, 2006.

From the *RAFT Institute of Plastic Surgery, Mount Vernon Hospital, Middlesex, UK; and †Rhytec Ltd, Hungerford, Berkshire, UK.

This paper has been presented at the American Society for Laser Medicine and Surgery meeting, April 2005, and was chosen for its excellence in the specialty of dermatology/plastic surgery, winning the Student/Resident Research Award.

There were no financial or personal relationships between the authors from the RAFT institute and with other people or organizations that could inappropriately influence the work submitted. The authors from Rhytec supplied the PSR apparatus and technical advice needed for this study but did not contribute to or have any say in the running of the study, interpretation of the results, or writing this paper.

Reprints: Matthew J. Potter, MRCS, The RAFT Institute of Plastic Surgery, The Leopold Muller Building, Mount Vernon Hospital, Northwood, Middlesex, HA6 2RN, UK. E-mail: mattpotters@hotmail.com.

Copyright © 2007 by Lippincott Williams & Wilkins

ISSN: 0148-7043/07/5806-0608

DOI: 10.1097/01.sap.0000252481.84134.fe

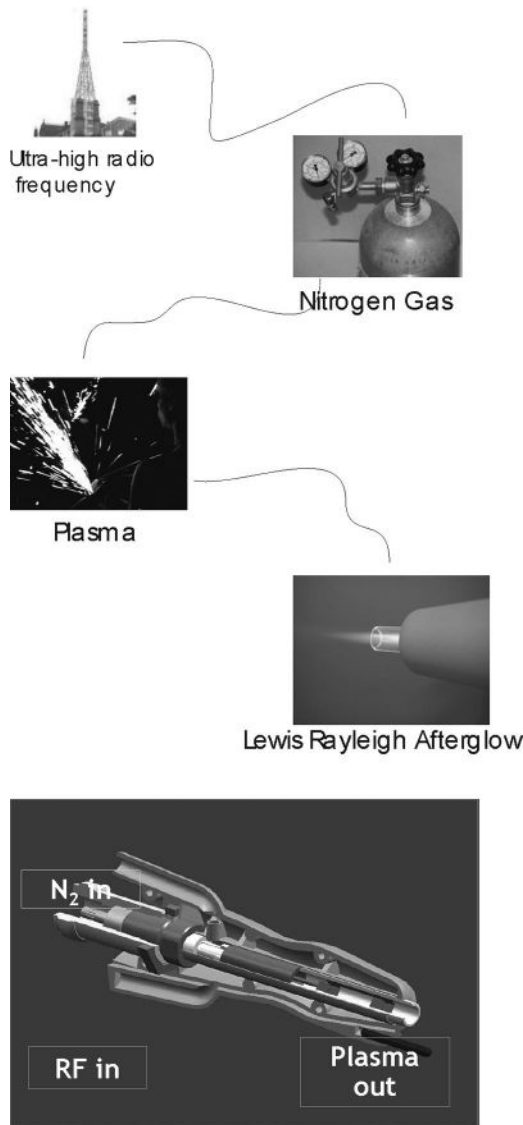


FIGURE 1. Diagrammatic illustrations of plasma formation by PSR (upper) with cutaway diagram of the handpiece (lower).

Control of the RF power level and pulse width allows a precise amount of energy to be delivered to the PSR handpiece in which the plasma is created. The plasma consists of highly excited ionized gas and is associated with a visible purple plume known as the Lewis-Rayleigh afterglow. Precise control of the radiofrequency energy allows the amount and timing of the plasma with the remaining unionized gas to be set. The plasma decays in a defined manner, releasing the energy used to create it. Controlled tissue ablation is followed by a stream of nitrogen gas, which has a cooling effect and also limits potential harmful oxidation of tissues by displacing air. Throughout the time of the RF pulse, the power level is monitored and any unacceptable deviation results in halting of generator operation. Within the handpiece, the plasma chamber initiates plasma generation

and ensures efficient coupling of RF energy to the plasma as it propagates through the chamber (Fig. 1, lower). While ionization occurs within the plasma chamber, the plasma is essentially neutral (nonionized) once it exits the nozzle. There is therefore insignificant radiation or coupling of RF to the patient or others. The RF pulse width is varied to provide a range of energies from 1-J pulse to 4-J pulse; the width is 15 ms. One can adjust the energy in 0.1-J steps.

There is no particular chromophore, and so the energy delivered is not potentially dependent on skin type.

Preclinical studies have demonstrated that PSR produces similar clinical and histologic effects to a standard CO₂ laser and with similar rates of healing, though these effects are fluence dependent. PSR has been proven to be effective in the treatment of benign skin lesions, with minimal sequelae.³

This paper aims to investigate PSR as a potential tool for facial rejuvenation by examining the results of a single treatment of PSR on the improvement in appearance of acne scarring and fine lines in a white population.

MATERIALS AND METHODS

This investigation was undertaken according to the principles of clinical investigation, with approval from the local ethics committee and complying with annex VIII and X of the medical devices directive 93/42/EEC and principles of clinical investigation BSEN 540.

Patient Selection/Procedure

Twelve patients were recruited with facial acne or fine lines, all of Fitzpatrick I and II skin type. One patient failed to attend follow-up. Of the 11 that completed the study (1 male, 10 female), 4 had fine lines, 8 had acne scarring, and 1 had both. Exclusion criteria were history of adverse scarring, recent laser/resurfacing surgery (within the last 12 months), and imminent strong sun exposure. Following full informed consent, patients underwent preoperative photography and silicone impression molding (Fig. 2, middle). Treated areas were anesthetized using 1% lignocaine. A single surgeon performed all the rejuvenation surgery (Fig. 2, upper). The plasma device (6-mm spot size) was held 5 mm perpendicular to the defect. Energy levels (1–4 J) and passes varied only according to the extent of the disease (Table 1). Patients underwent a single treatment. Postoperatively, wounds were hydrated with chloramphenicol ointment (Pharmacia). Patients were advised to avoid sun exposure, to apply twice daily hydroxyquinone 2% and sun block for 1 month, and to finish a week's course of flucloxacillin 500 mg, 4 times daily, and acyclovir 200 mg, 5 times daily.

All patients were reviewed immediately postoperatively, at 10 days, 3 months, 6 months, and at 2 years. Objective and quantitative assessment of defect change was made by digital photography and silicone molding of the facial defects before and at each postoperative assessment.

Molding and Assessment of Wrinkle Depth

An accurate assessment of defect depth was made using a silicone elastomer mold preparation (MED-6382; McGahn Nusil Corp, Carpinteria, CA). The elastomer was prepared by mixing the silicone monomer with the provided catalyst,

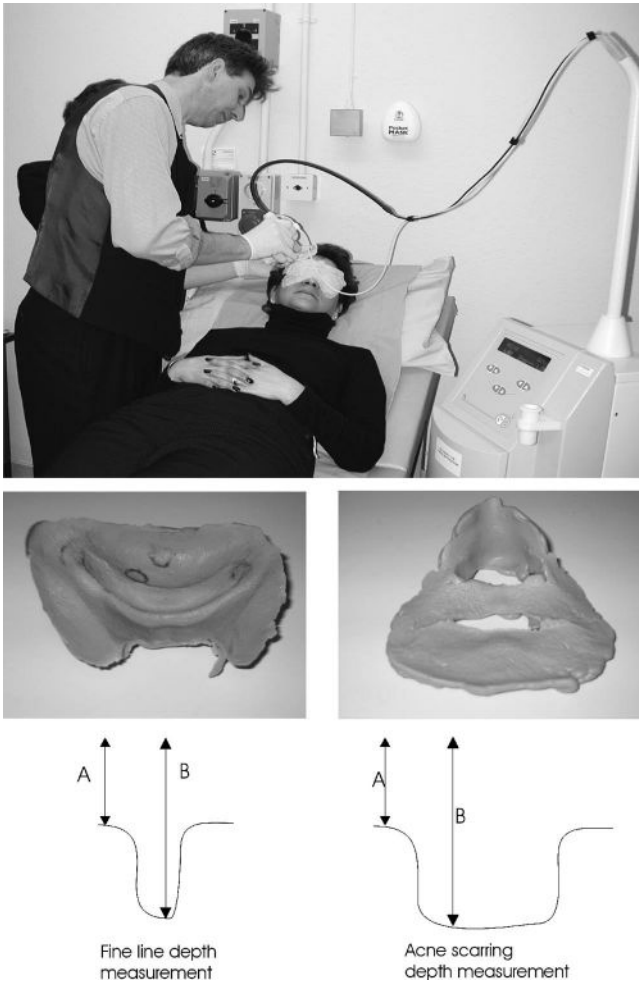


FIGURE 2. A single surgeon performed all plasma resurfacing using a 6-mm diameter nozzle (upper). Silicone molds were taken preoperatively and at each and every follow-up (middle). These were analyzed for depth of defect using a published light microscope method⁵ (B-A, lower).

TABLE 1. Number of Patients Undergoing Specific Levels of PSR Energy and the Number of Passes per Patient Involved in Each of the Treatment Groups

No. Joules Applied to the Skin in the Single Pass	No. Patients Given Specific Range of PSR Energy to Acne Scars	No. Patients Given Specific Range of PSR Energy to Fine Lines
1–2 J	1	4
2–3 J	6	1
3–4 J	7	0
No. Passes of PRS Used in the Single Treatment	No. Patients Being Treated for Acne Scarring	No. Patients Being Treated for Fine Lines
1	5	4
2	3	0

TABLE 2. Subjective Parameters Assessed by Patients Postoperatively and at Each Follow-up

Clinician-Assessed Parameters	Linear Analogue Scale	Results
Skin irregularity removed	0 to 4, not removed to 100% removed	All had 100% initial removal of lesion
Degree of reepithelialization	0 to 4, no epithelialization to completely epithelialized	All were reepithelialized at all reviews
Erythema	0 to 4, absent to severe	No erythema seen at review; maximum erythema at day 4
Hypopigmentation	0 to 4, absent to severe	No hypopigmentation seen
Hyperpigmentation	0 to 4, absent to severe	No hyperpigmentation seen
Area of scar	mm ²	No scarring seen
Height of scar	mm ²	No scars seen

producing an elastomer suspension, this then applied to the facial irregularity. The low viscosity of the elastomer promotes penetration into all skin irregularities.⁴ Once prepared, the elastomer hardens on the facial defect within 5–10 minutes, producing a high-resolution permanent negative of the skin surface. All molds were left to completely cure (24 hours) before depth assessment.

Defect depth was assessed using a microscope technique with side lighting.⁵ This involves calibrating the depth of focus of the microscope against an object of known height/depth. Using the calibrated microscope, one can objectively assess for the difference in depth of other objects, such as molds, comparing the different lengths of focus and hence calculating the depth in millimeters. For each area treated and for each patient, 5 specific areas were analyzed for defect depth. These identical sites were compared for change between the molds taken before and at each follow-up.

Differences in depth percentage from the preoperative molds were calculated for each follow-up period. Data were analyzed by Mann-Whitney rank sum test using SigmaStat 2 software (Jandel).

In addition patients were questioned about complications (pigmentation), discomfort, pain, itching, downtime, time for all raw areas to heal (time to reepithelialization), and duration of erythema (Tables 2 and 3).

RESULTS

PSR Gives Minimal Postoperative Complications

Patients following both fine line and acne scarring treatment developed no postoperative itching, lumpiness, or pain. All patients had initial loss of epidermal continuity, at least to some extent, that had fully epithelialized at the 10-day review. Greatest time for epithelialization was 5 days. Maximum erythema occurred at day 4. This dissipated by day 6. Despite the loss of epidermal continuity, there was no weep-

TABLE 3. Subjective Parameters Assessed by a Single Clinician Postoperatively and at Each Follow-up

Patient-Assessed Parameters	Linear Analogue Scale	Results
The amount of pain after/during the procedure	1 to 10, no pain to intolerable pain	No pain noted postprocedure, Average pain perioperatively, 4
The degree of redness of the area treated	1 to 10, no redness to intolerable redness	Average score, 1
The lumpiness of the treated area	1 to 10, no lumps to prolific lumpiness	Average score, 1
The degree of itching	1 to 10, no itching to intolerable itching	Average score, 1
The overall satisfaction with the procedure	1 to 10, completely dissatisfied to completely satisfied	Average score, 3
Time for all raw areas to heal (time to reepithelialization)	Number of days	1 to 5 days, mean = 3 days
Downtime	Number of days	1 to 5 days, mean = 3

ing or exudate. There was no hyper/hypopigmentation during the immediate follow-up (6 months or less) or at the 2-year review. No patient was scarred from the PSR treatment. Downtime varied from 0 to 5 days; mean time was 3 days.

One patient was able to return to work immediately (Fig. 3 upper).

PSR Induces a Long-Term Reduction in Fine Line/Scar Depth

Mean depth of fine lines and acne scars preoperatively was 0.2 and 0.25 mm, respectively. Fine-line objective mold assessment showed a decrease in depth of defect of 39% at 10 days ($P = 0.004$, Mann-Whitney rank sum test; Fig. 3 middle). This decreased to 29% at 3 months and 24% at 6 months ($P = 0.005$, Mann-Whitney rank sum test; Fig. 4). There was no significant change in fine-line assessment between the 6-month and 2-year review. All were significantly different from the preoperative molding. Depths of lines were different between the 10-day and 6-month follow-up molds. The greatest percentage reduction in any one patient was in forehead fine lines, giving 55% reduction at day 10.

Acne-scarred patients had a 34% reduction in scar depth at 10 days, 26% at 3 months, and 23% at 6 months. All were significantly different from preoperative molds ($P = 0.001$, Mann-Whitney rank sum test; Fig. 3, lower; Fig. 5). There was no difference between the 10-day and 3-month molding, as well as the 3-month and 6-month molds. There was no significant change in scarring between the 6-month and 2-year review. Percentage wrinkle reduction at 6 months was significantly less than at 10 days.

Although the molds showed improvement in scar and wrinkle depth, patients' perception of the change due to treatment varied. Two were completely satisfied, 7 felt there had been an improvement but would have liked further change, and 2 patients could not see any noticeable difference.

DISCUSSION

This study has shown objectively that PSR produces a long-term reduction in depth of facial irregularity, along with minimal postoperative sequelae/morbidity. Fine-line depth reduction was maximal at 10 days (39%), with an attributable cause from edema; this depth reduction decreased to 24% at 6 months. PSR has been shown to produce a measurable improvement in skin irregularity and reduced morbidity compared with the standard CO₂ laser technique. While CO₂ lasers can achieve a 91% reduction in the depth of facial wrinkles measured using an identical molding technique,⁵ there is now great concern that the risk of hypopigmentation

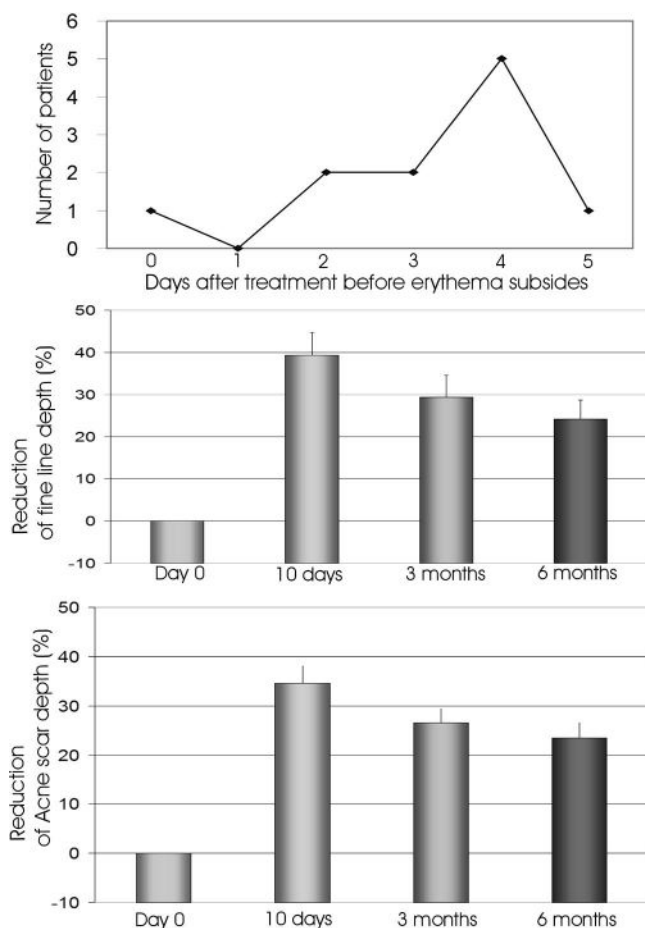
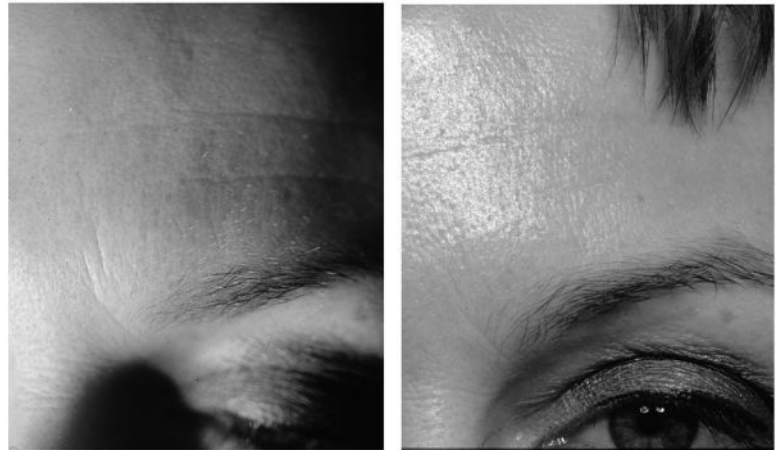

FIGURE 3. Patients were assessed for downtime (upper), with an average of 3 days. Maximum down time was 5, with 1 patient immediately returning to daily activities. Fine lines decreased on average by 39.3% at 10 days ($P = 0.004$, Mann-Whitney rank sum test, middle), with percentage reduction of defect depth decreasing to 24.0% at 6 months. Acne scarring had a 34.64% reduction at 10 days ($P = 0.001$, Mann-Whitney rank sum test, lower).

Patient 1



Patient 2

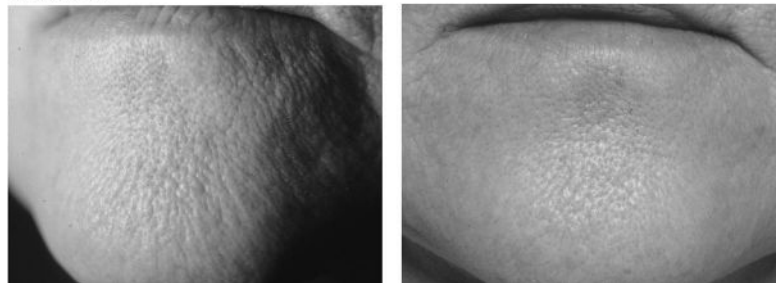
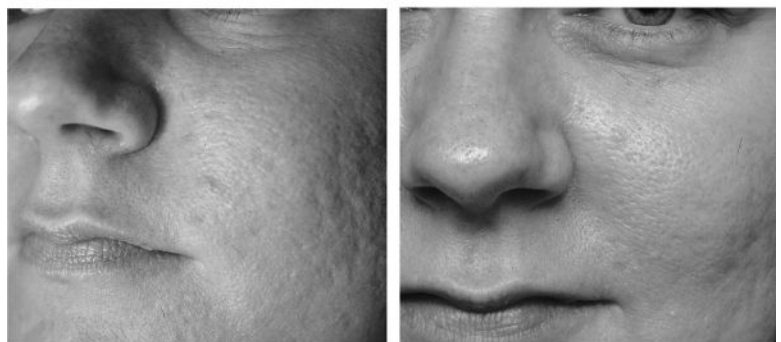


FIGURE 4. Fine-line treatment before (left) and at 6 months (right). Patient 1 had a 33.33% reduction in preoperative fine lines (upper left), as evidenced at the 6-month assessment (upper right). Patient 2 at 6 months (lower right) had fine lines of depth 42.5% less than at the preoperative state (lower left).

with the CO₂ laser is unacceptable. In this small series, 2 patients felt the PSR treatment had been a complete success. The other patients were concerned that despite an objective

change in the depth of the skin defect, they would prefer a more significant change. Nevertheless, 8 of the 11 patients requested repeat treatment at the end of the study.

Patient 3



Patient 4

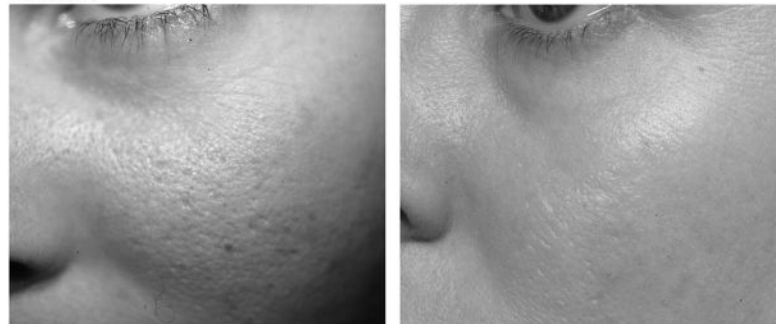


FIGURE 5. Acne scar treatment before (left) and at 6 months (right). Patient 3 had a 28.72% reduction in preoperative acne scar depth (upper left), as evidenced at the 6-month assessment (upper right). Patient 4 at 6 months (lower right) had acne scars of depth 20.45% less than at the preoperative state (lower left).

An encouraging feature of the PSR treatment was the minimal morbidity. While no scarring was noted at any follow-up period, patients did suffer from erythema, albeit for short periods (mean, 3 days). This contrasts significantly with the 3–4 weeks of erythema commonly seen with Er:YAG and 5 weeks with CO₂ lasers.⁶ Studies investigating postlaser sequelae have found subepidermal fluid-filled cavities in 19% of patients⁷; this was not the case with PSR. Nonetheless, patients did take 5 days to fully epithelialize, similar in time course to CO₂ and Er:YAG lasers.⁶

A single patient in our study was able to immediately return to work; all other patients had downtimes of less than 5 days.

One of the most common side effects associated with laser resurfacing is pigmentation change. Often transitional,⁸ it may arise within 3 weeks⁹ and may be permanent or fade within a year.⁹ Hyperpigmentation may be as high as 46% in cases treated with CO₂ lasers.⁶ Hypopigmentation, though less likely (4% of cases treated with Er:YAG),¹⁰ represents a far more resilient and potentially permanent side effect of laser therapy on all skin types. In this study, no pigmentary changes were seen at any stage of follow-up. This may be due to the lack of a particular chromophore on which the PSR acts. Nevertheless, this study was limited to Fitzpatrick skin types 1 and 2, and further studies are needed to address the effects of PSR on darker skin types.

Alternative forms of rejuvenation therapy, including chemical peels, in some studies are thought to be less effective than laser therapy.¹¹ Papers comparing CO₂ laser to dermabrasion have found no difference in wrinkle score at 4 to 6 months, suggesting that both methods are equally efficacious; nevertheless, like PSR, dermabrasion was associated with less erythema than laser therapy.^{11,12} The effectiveness of other interventions such as hydroxyl acids and natural polysaccharides is not clear.^{12,13} It would be interesting to investigate and compare PSR to further alternative forms of facial rejuvenation therapy.

CONCLUSIONS

The main objective with rejuvenation is to achieve selective heat-induced denaturation of dermal collagen, leading to subsequent reactive synthesis of neocollagen without significantly preventing epidermal regeneration, thus minimizing side effects.

This study, though limited in subject number, presents a novel rejuvenation device for facial scarring and fine lines. It has found that, in a small study size, PSR provides long-term measurable improvement in 2 different facial pathologies, without the side effects commonly associated with laser surgery.

In providing the clinician with a resurfacing tool that generates long-term results with minimal downtimes, it allows patients to have an effective treatment with minimal impact on day-to-day activities.

Further studies need to address the effects of multiple/repetitive PSR dosing regimens, as well as effects of PSR on higher-grade Fitzpatrick skin types. Nevertheless, the authors feel this paper is an important step in the investigation of a promising tool in the field of facial rejuvenation.

REFERENCES

1. Papadavid E, Katsambas A. Lasers for facial rejuvenation: a review. *Int J Dermatol*. 2003;42:480–487.
2. Bernstein LJ, Kauver ANB, Grossman M, et al. The short and long term side effects of carbon dioxide laser resurfacing. *Dermatol Surg*. 1997; 23:519–525.
3. Potter MJ, Harrison RK, Ramsden A, et al. A randomised control trial comparing plasma skin resurfacing (PSR) with carbon dioxide laser in the treatment of benign skin lesions. Joint International Laser conference; Edinburgh, 2003.
4. Morris WJ, Dische S, Mott G. A pilot study of a method of estimating the number of functional eccrine sweat glands in irradiated human skin. *Radiother Oncol*. 1992;25:49–55.
5. Grover R, Grobbelaar AO, Morgan BDG, et al. A quantitative method for the assessment of facial rejuvenation: a prospective study investigating the carbon dioxide laser. *Br J Plast Surg*. 1998;51:8–13.
6. Tanzii EL. Single pass carbon dioxide versus multiple pass Er:YAG laser skin resurfacing: a comparison of postoperative wound healing and side effect rates. *Dermatol Surg*. 2003;29:80–84.
7. Chan H-H, Lam L-K, Wong D-S, et al. Use of 1,320 nm Nd:YAG laser for wrinkle reduction and the treatment of atrophic acne scarring in Asians. *Lasers Surg Med*. 2004;34:98–103.
8. Lent WM, David LM. Laser resurfacing: a safe and predictable method of skin resurfacing. *J Cutan Laser Ther*. 1999;1:87–94.
9. Kim Y-J, Lee H-S, Son S-W, et al. Analysis of hyperpigmentation and hypopigmentation after Er:YAG laser skin resurfacing. *Lasers Surg Med*. 2005;36:47–51.
10. Wenstein C. Erbium laser resurfacing: current concepts. *Plast Reconstr Surg*. 1999;103:602–616.
11. Samuel M, Brooke RC, Hollis S, et al. Interventions for photodamaged skin. *Cochrane Database Syst Rev*. 2005;25:CD001782.
12. Hirsch RJ, Dayan SH, Shah AR. Superficial skin resurfacing. *Facial Plast Surg Clin North Am*. 2004;12:311–321.
13. Fulton JE, Porumb S. Chemical peels: their place within the range of resurfacing techniques. *Am J Clin Dermatol*. 2004;5:179–187.